

FIGYELEM!

**A DOKUMENTUM A NYUGALOM
MEGZAVARÁSÁRA ALKALMAS
KÉPEKET TARTALMAZ!**



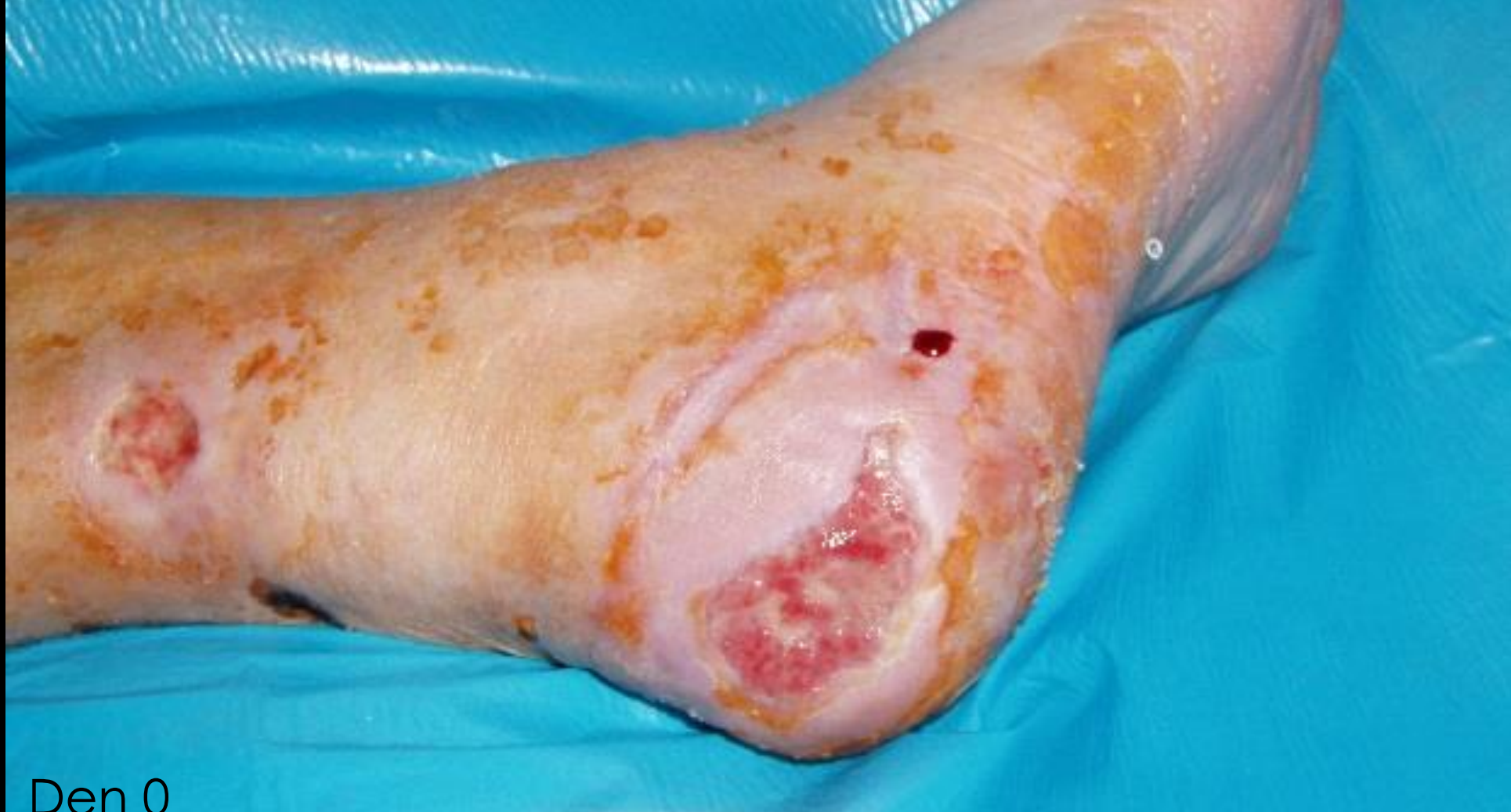Sorelex

ZJEDNODUŠTE HOJENÍ



Case I - Diabetic foot

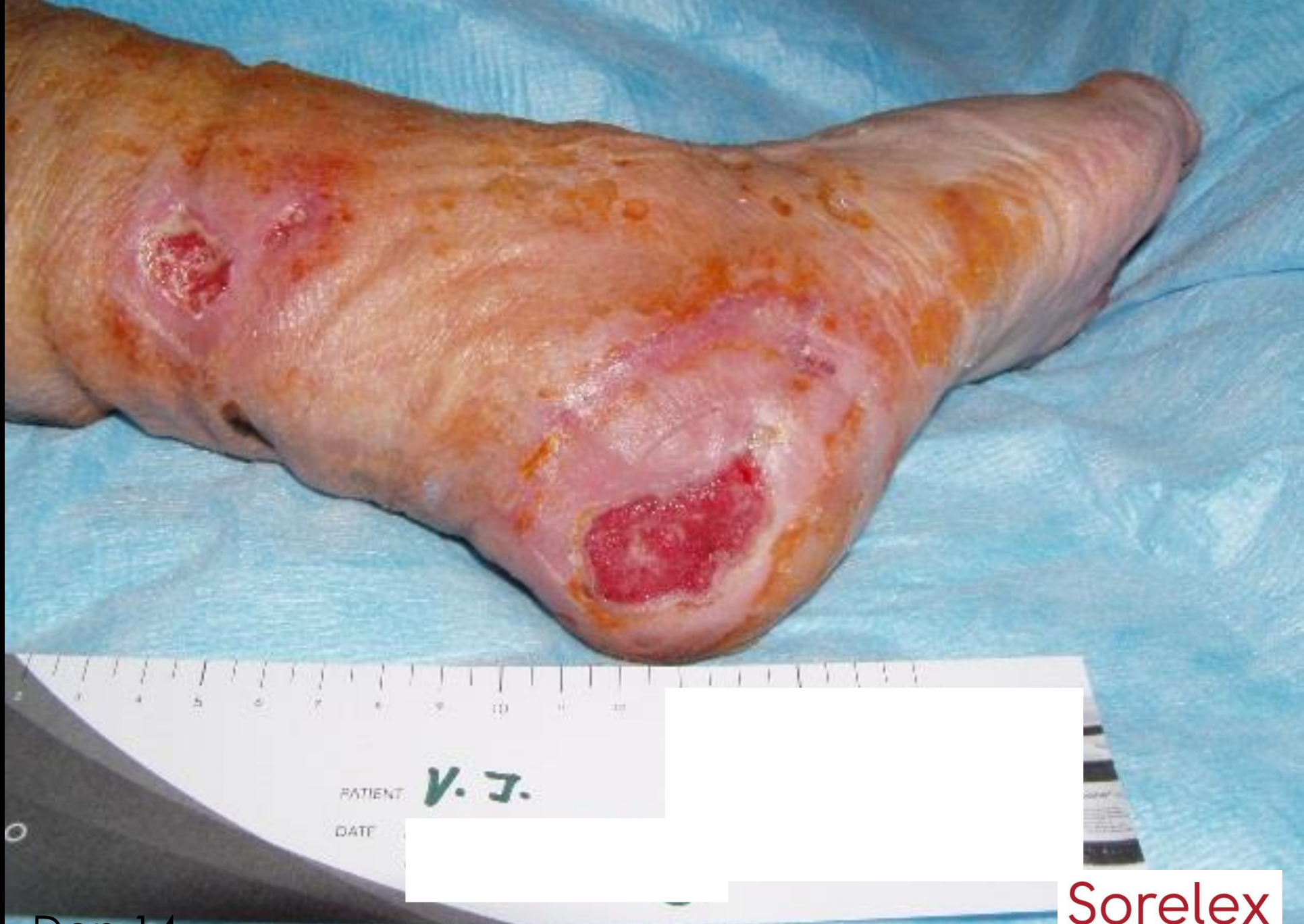Patient I: Female, 78 years old, leg ulcer, cardiac ischemia, chronic obstructive pulmonary disease, lower limb ichemes



Den 0

PATIENT V.J.
DATE
bejo

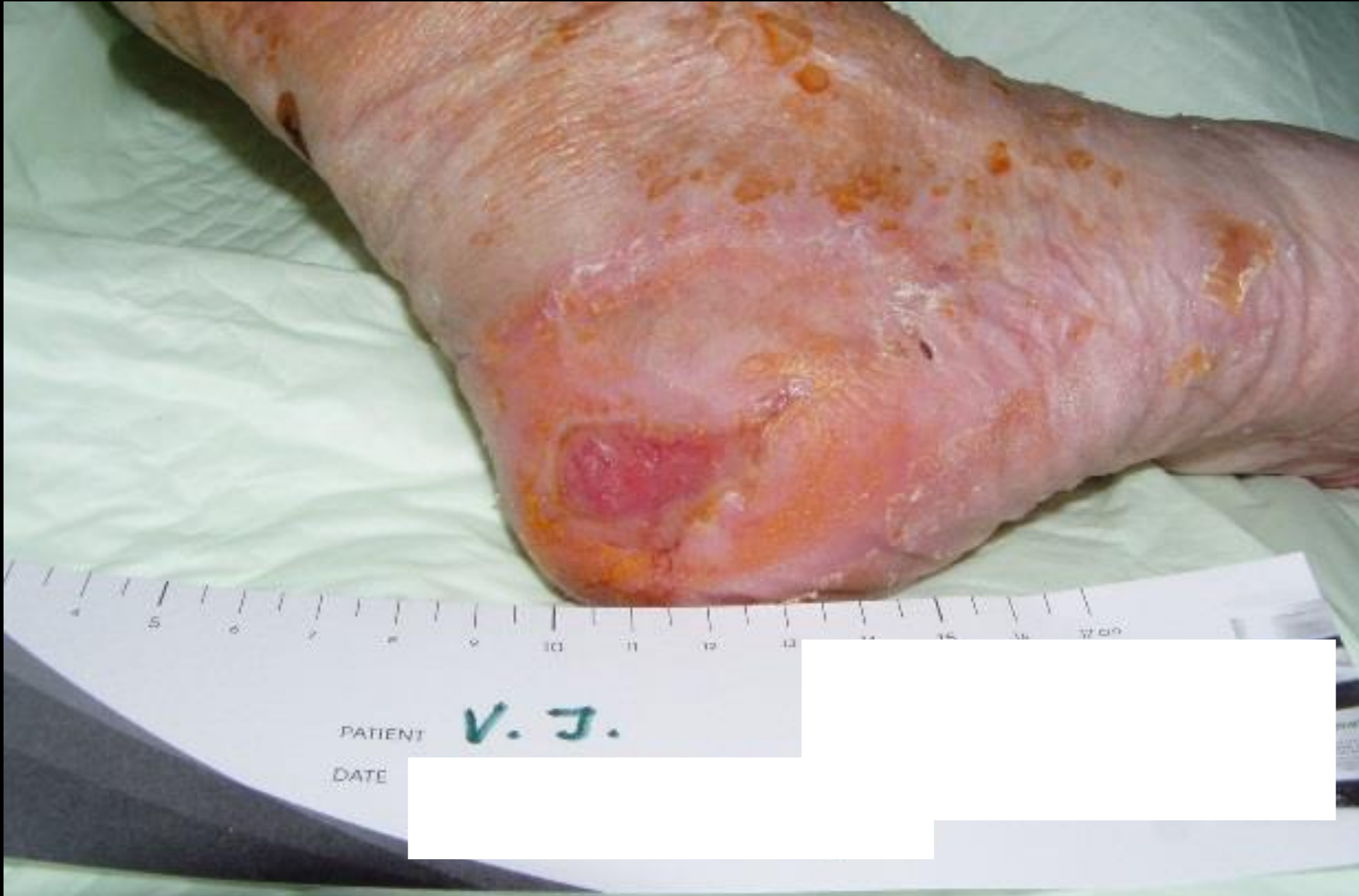Sorelex
ZJEDNODUŠTE HOJENÍ



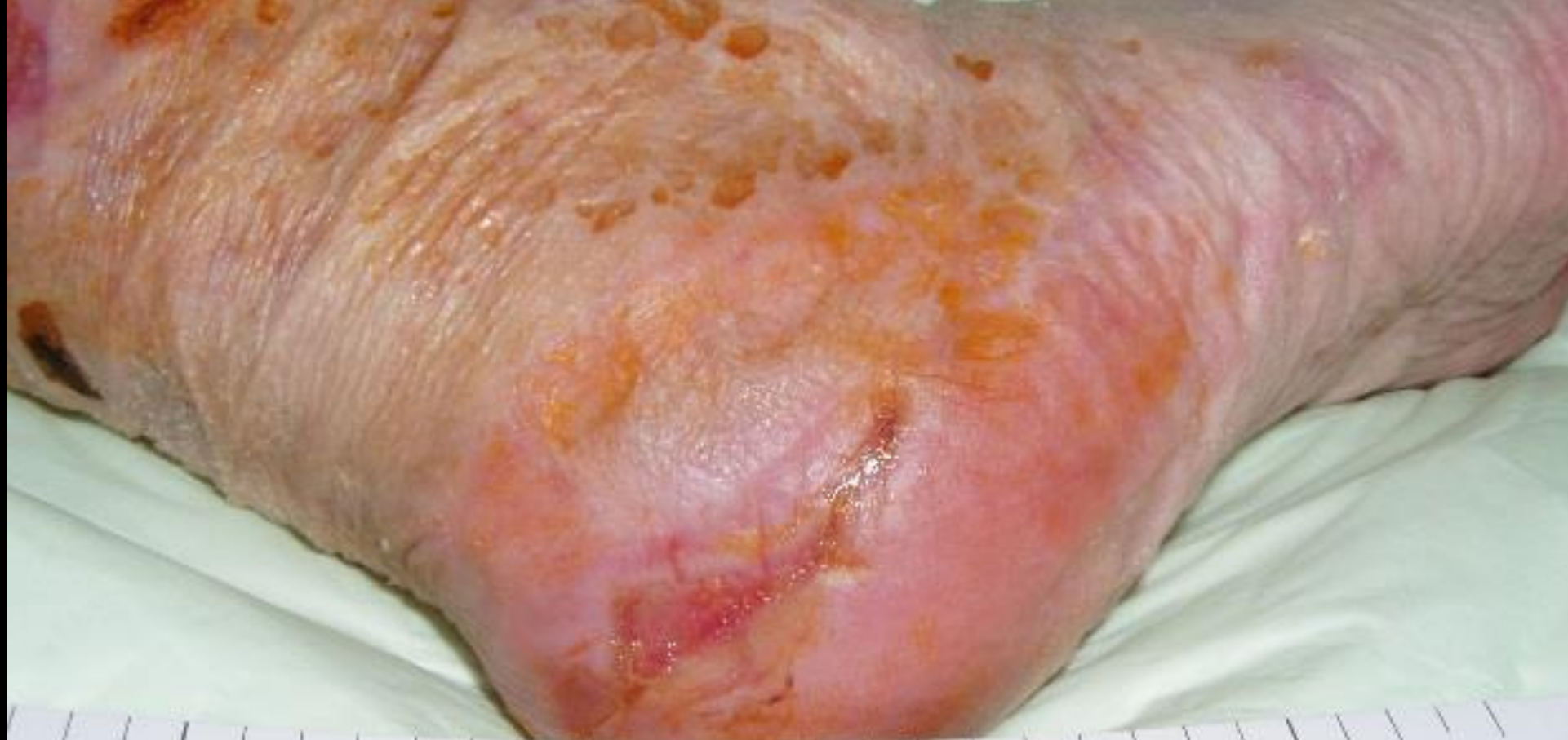PATIENT: V. J.
DATE

Den 14

Sorelex
ZJEDNODUŠTE HOJENÍ



Den 28



Den 56

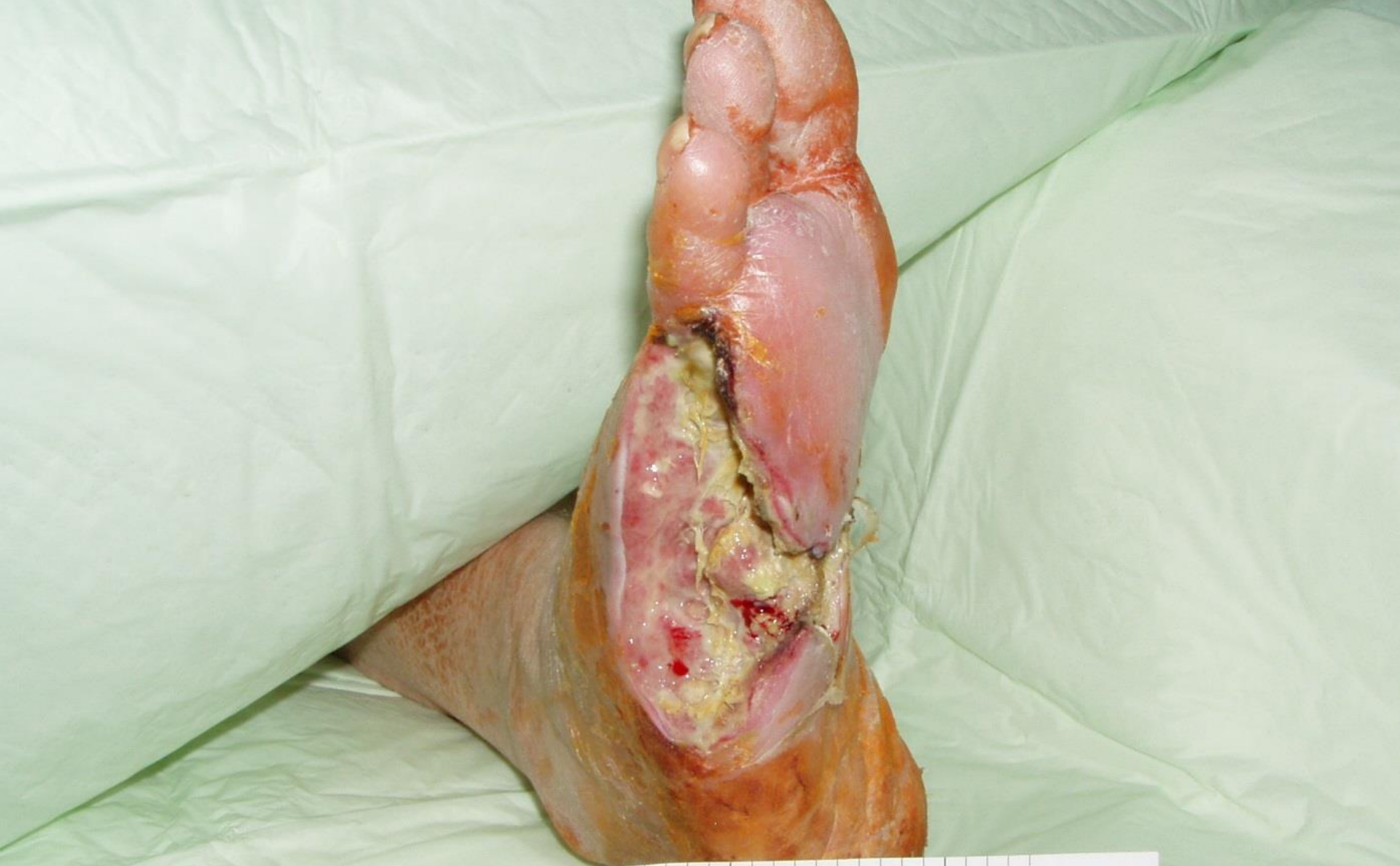PATIENT

V. J.

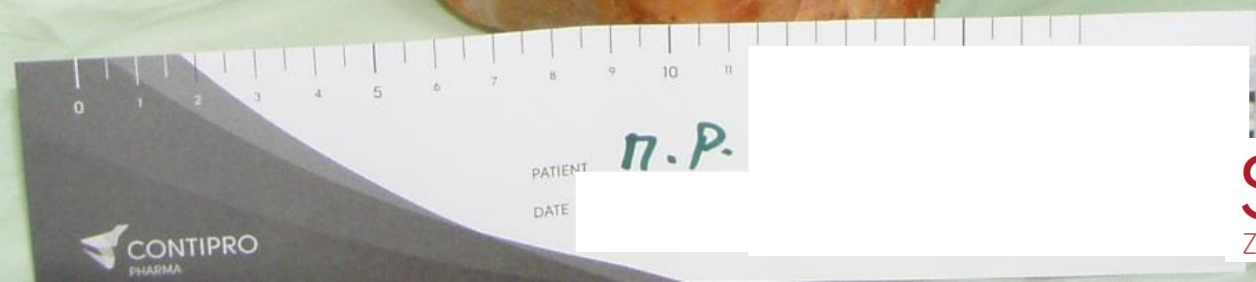
Sorelex
ZJEDNODUŠTE HOJENÍ

Case II - Diabetic Foot

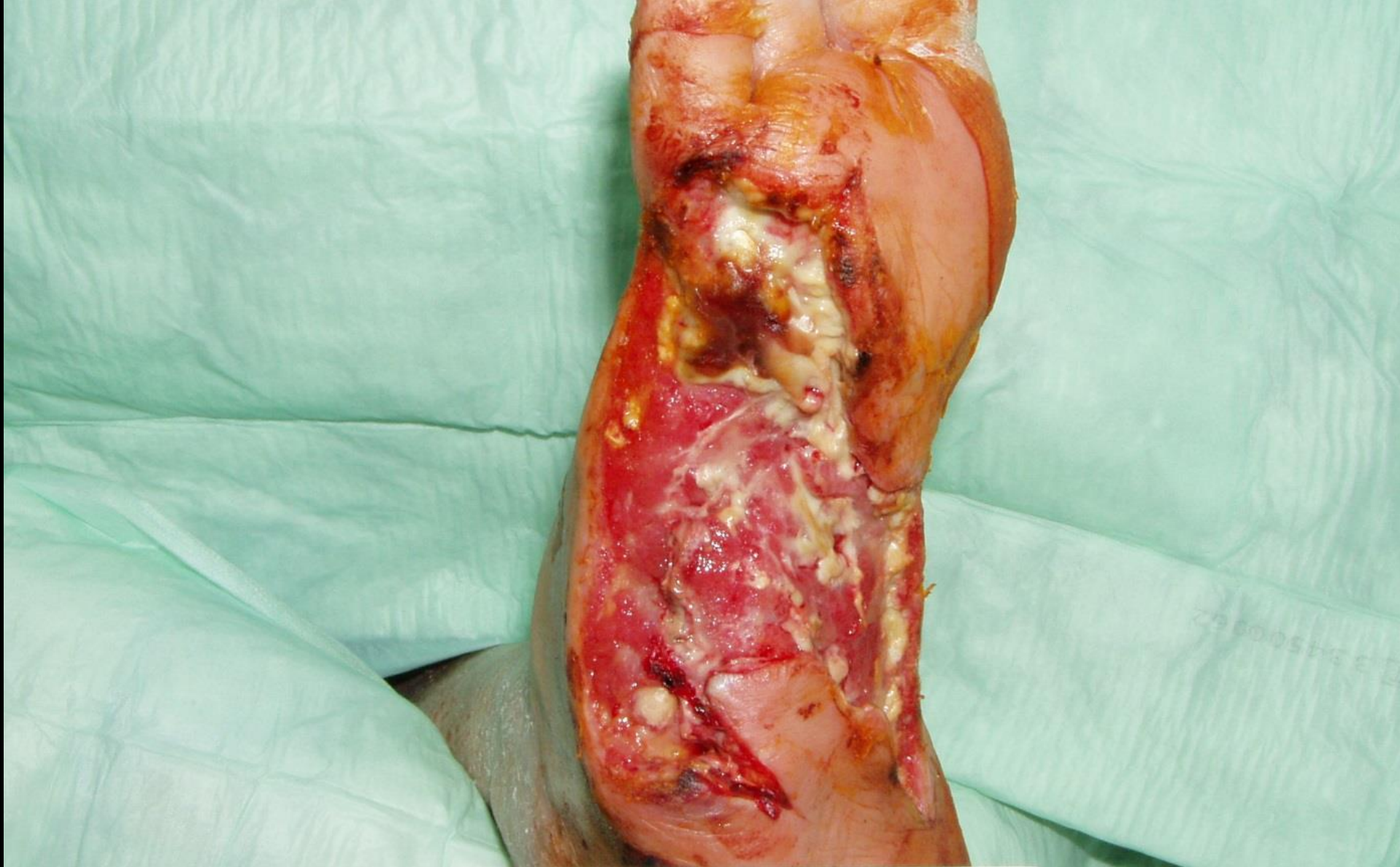
Patient II: non-healing diabetic ulcer after amputation of the 4th and 5th toes, later amputation necessity also 3rd and 2nd toes



Den 0



Sorelex
ZJEDNODUŠTE HOJENÍ



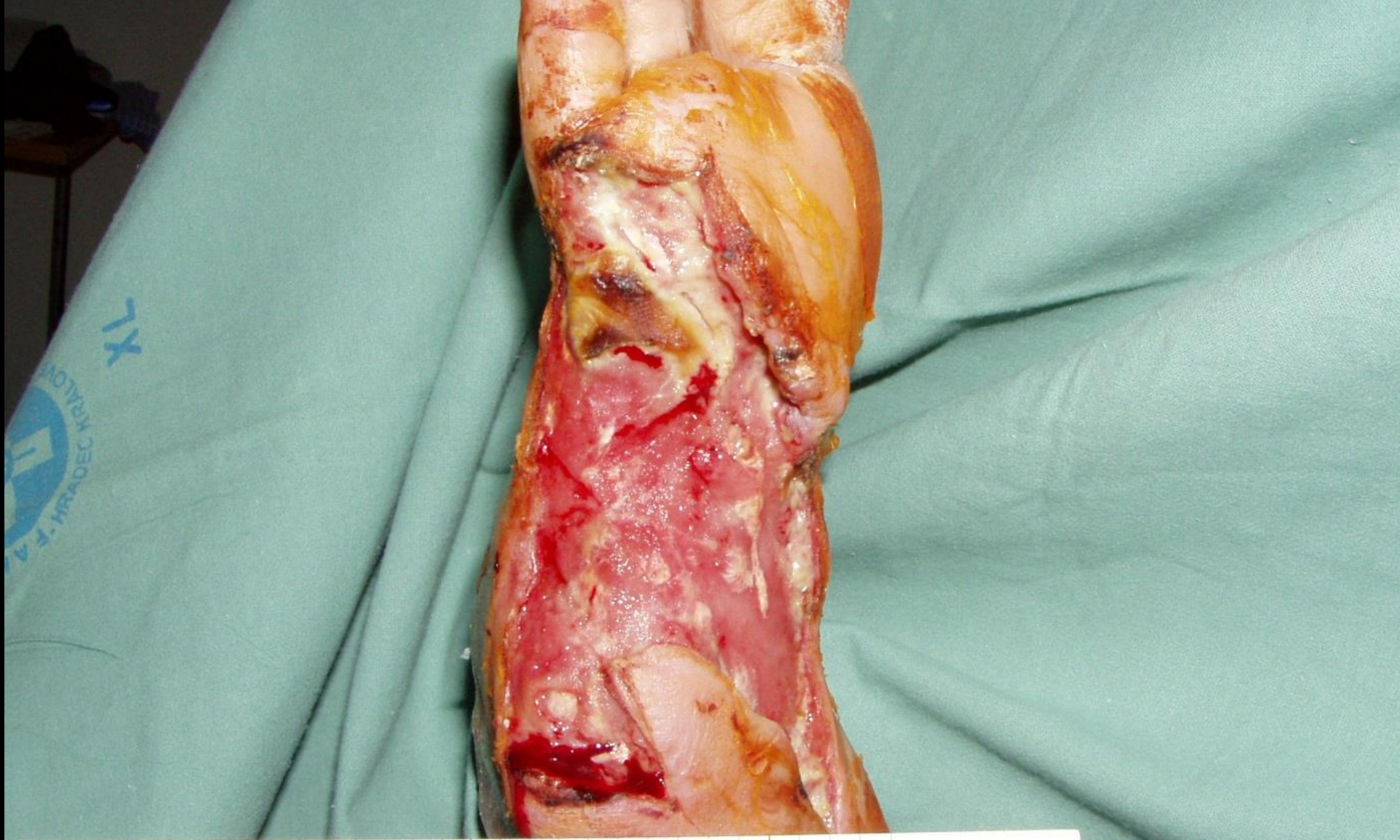Den 12

PATIENT

M.P.



Sorelex
ZJEDNODUŠTE HOJENÍ

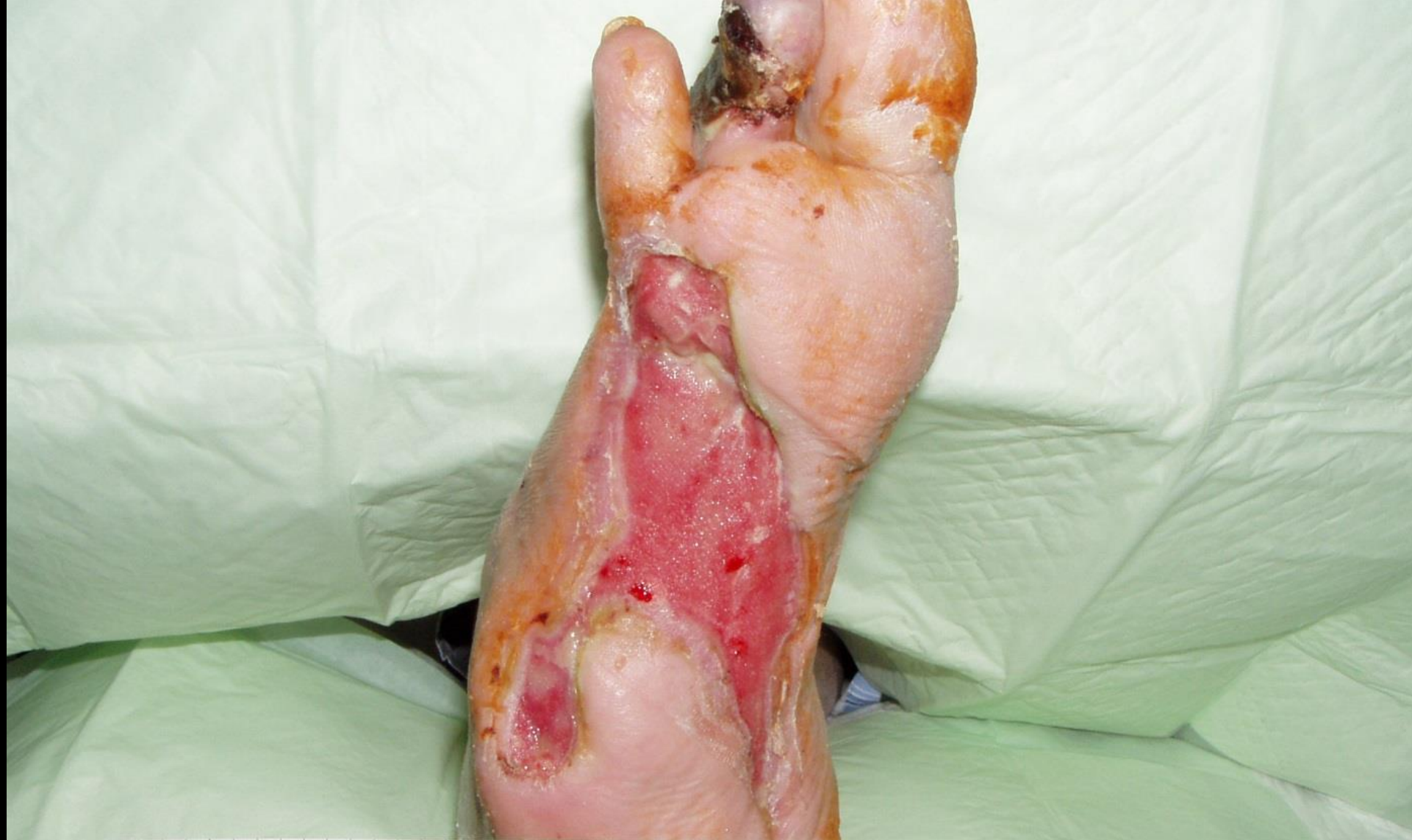

Den 21

PATIENT **M.P.**

DATE

Sorelex
ZJEDNODUŠTE HOJENÍ

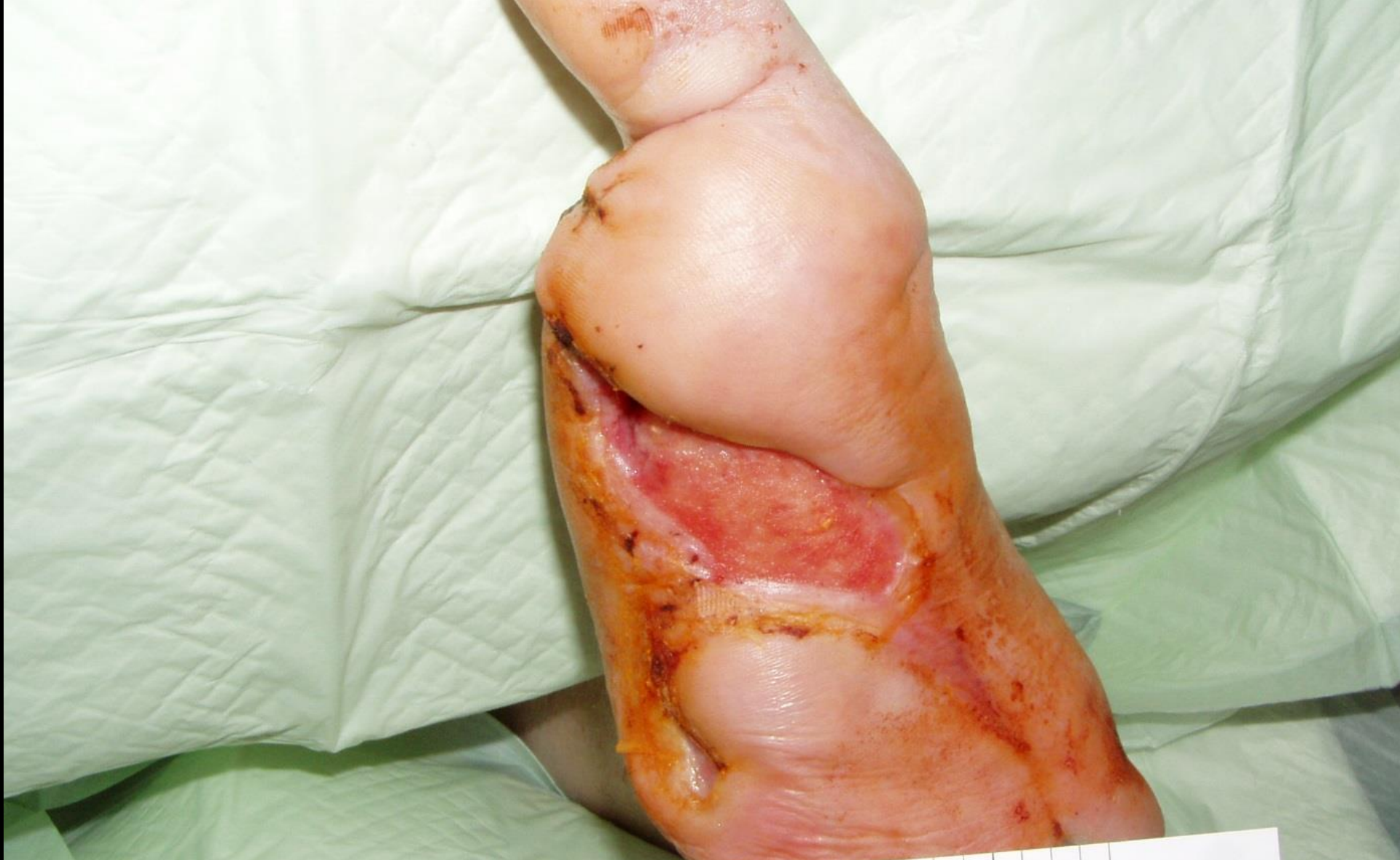

Den 71

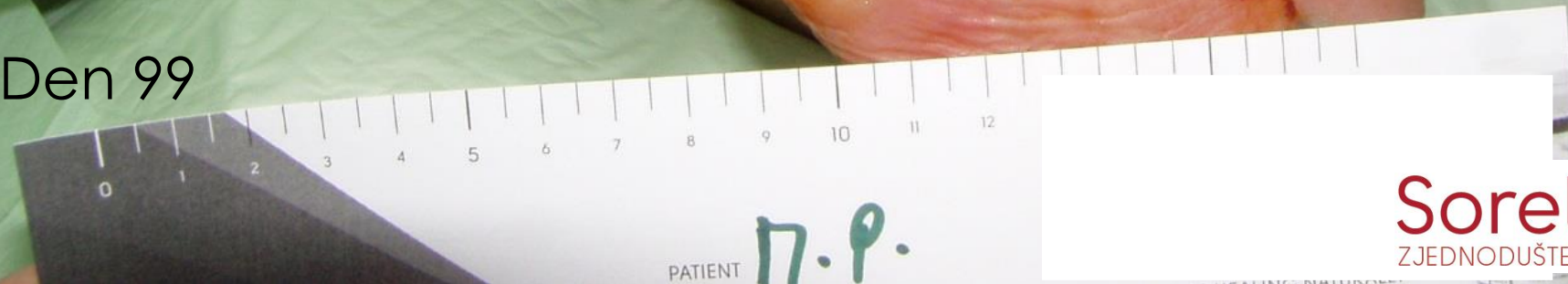PATIENT *n.p.*

CONTIPRO
PHARMA

Sorelex
ZJEDNODUŠTE HOJENÍ

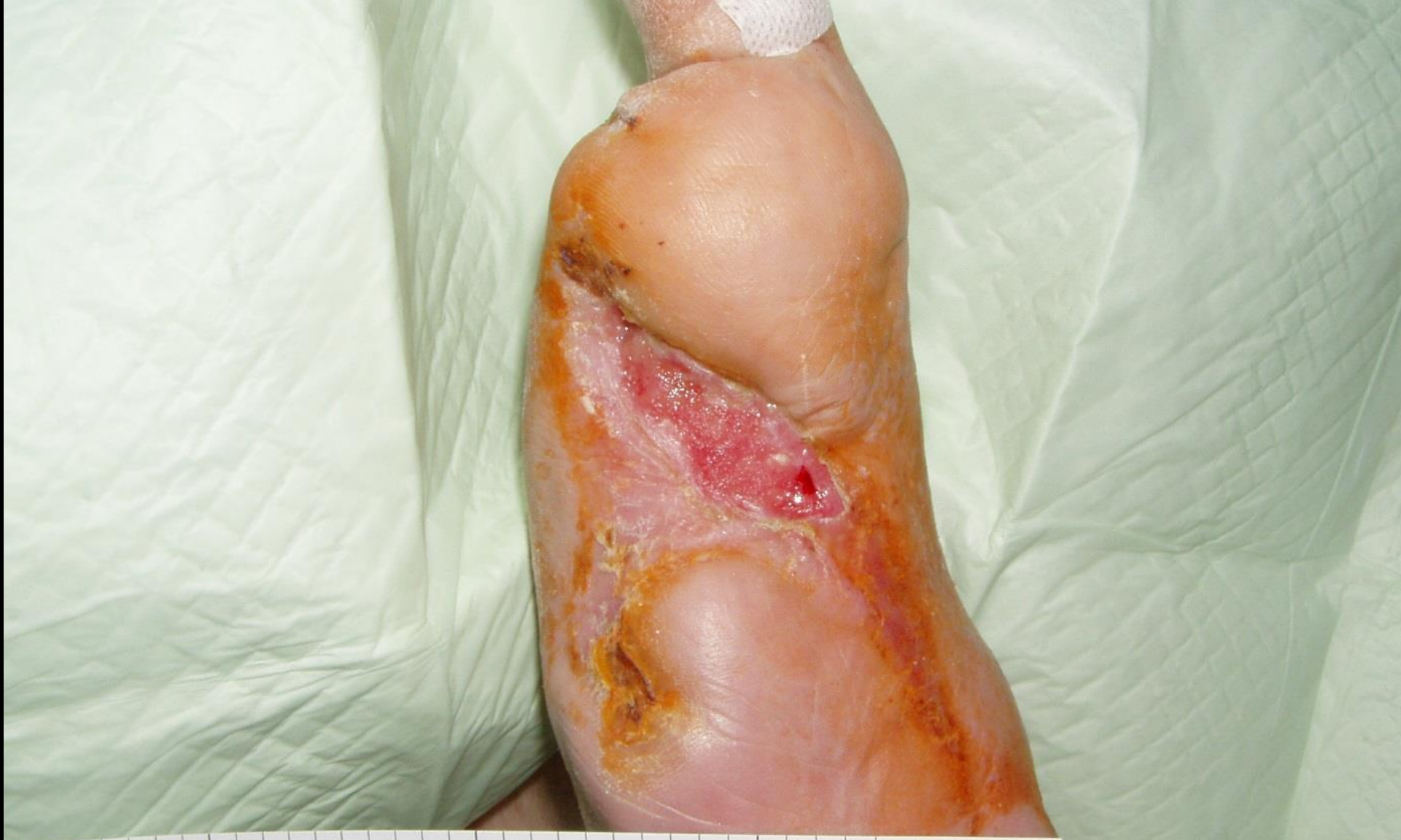


Den 99



PATIENT 17.P.

Sorelex
ZJEDNODUŠTE HOJENÍ



Den 121

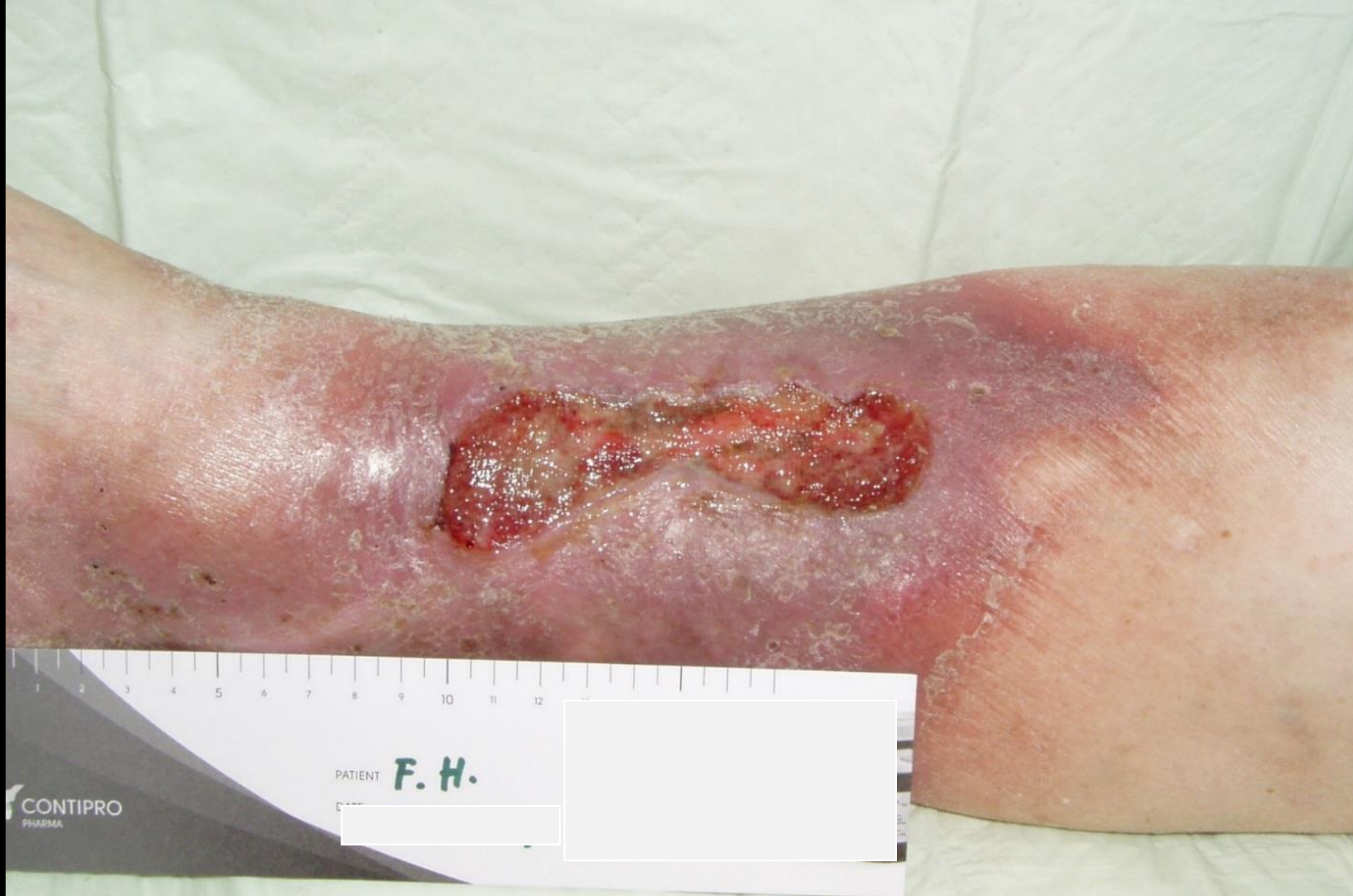PATIENT **M. P.**
DATE

Sorelex
ZJEDNODUŠTE HOJENÍ

ONTIPRO

Case III - Leg ulcer

Patient III: female, F.H., patient suffering from chronic venous insufficiency, upper leg ulcer treated for 3 years without result



Den 0

Sorelex
ZJEDNODUŠTE HOJENÍ

Den 17

 **CONTIPRO**
PHARMA

PATIENT

F. H.

DATE

Sorelex
ZJEDNODUŠTE HOJENÍ

Den 42



PATIENT F.H.

ONTIPRO
SRMA

Sorelex
ZJEDNODUŠTE HOJENÍ

Den 62

0 1 2 3 4 5 6 7 8 9 10 11

PATIENT **F. H.**

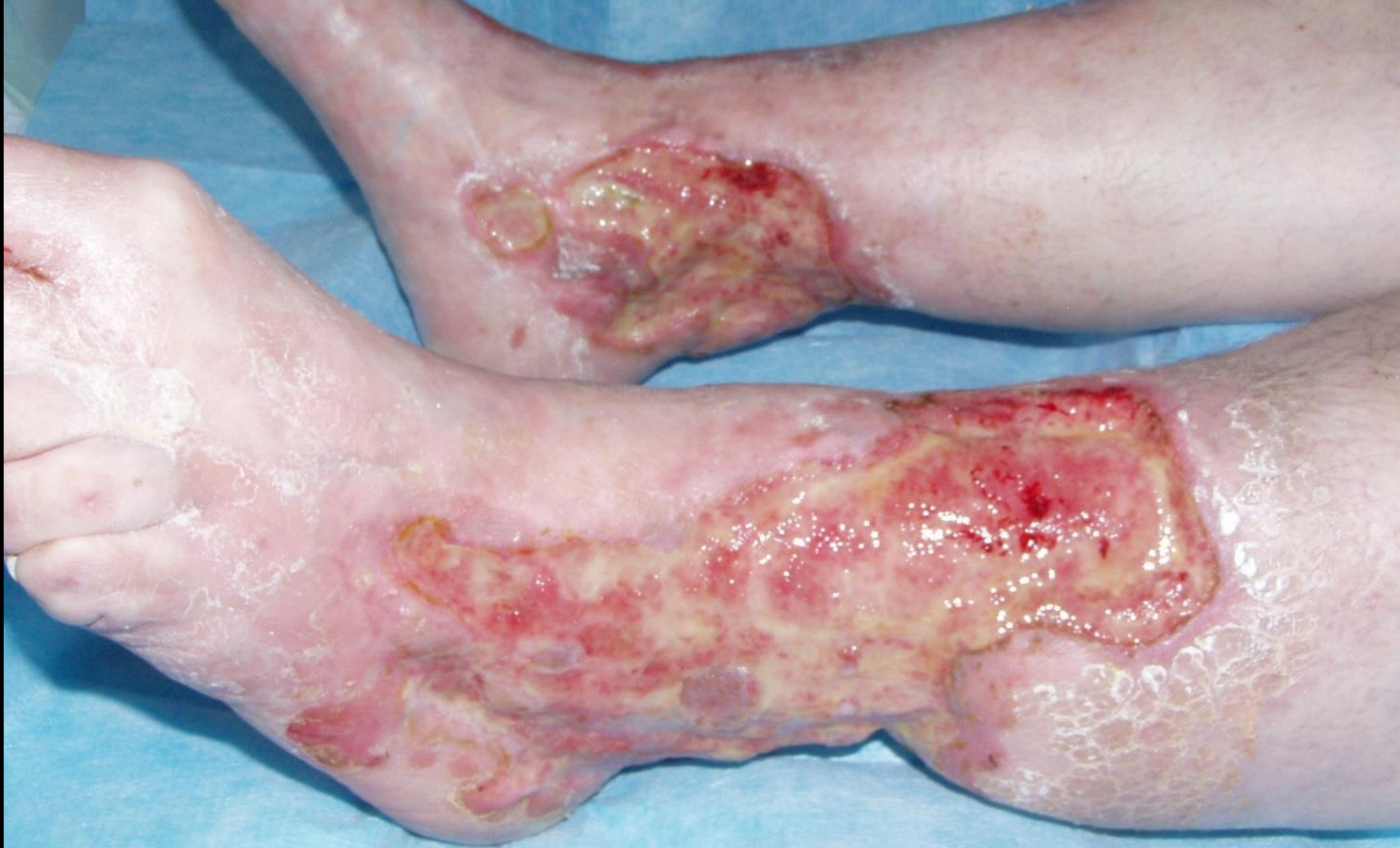DATE

 **CONTIPRO**
PHARMA


Sorelex
ZJEDNODUŠTE HOJENÍ

Case IV - Leg ulcer

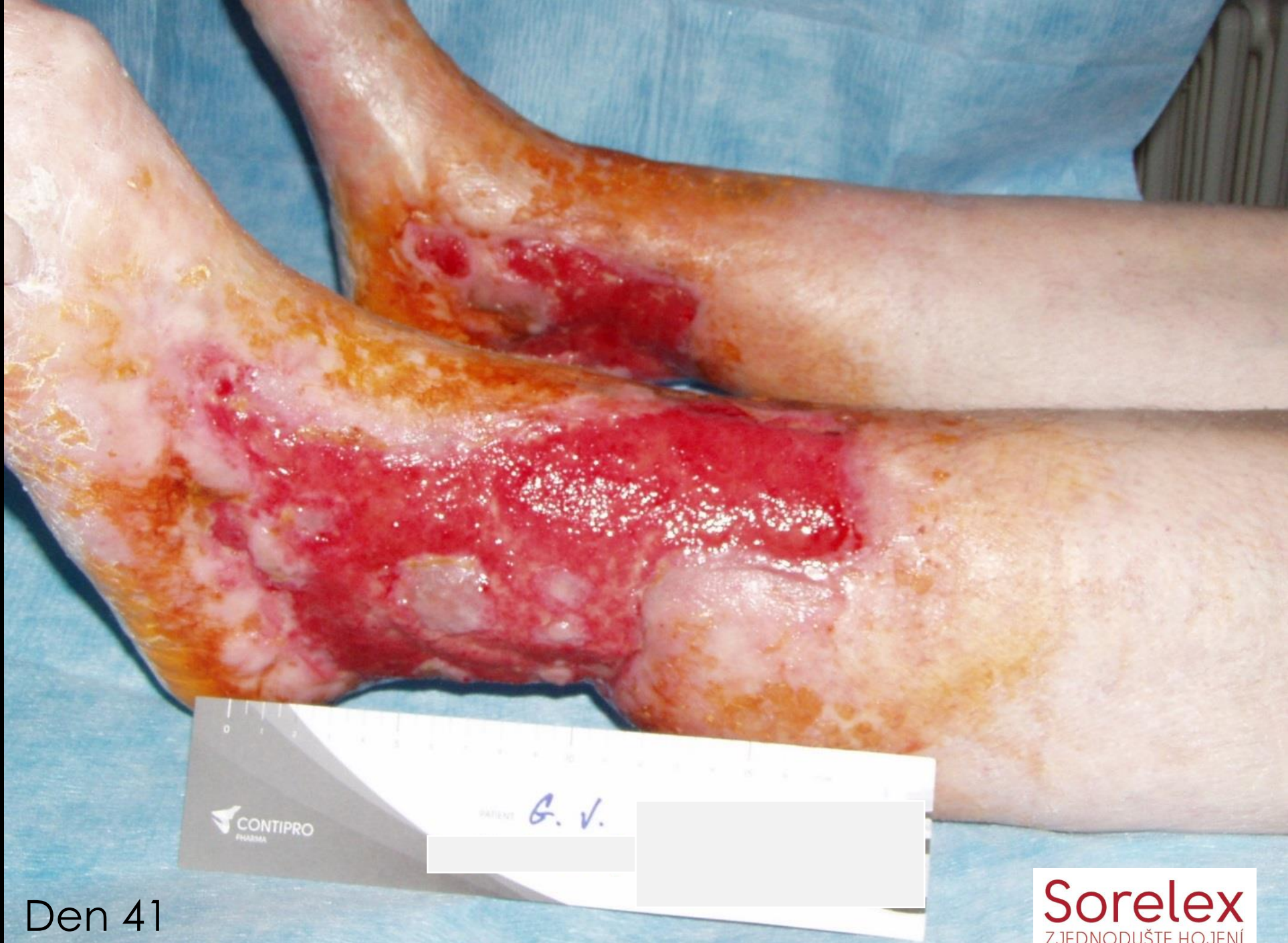- Patient IV: Male, G.J., chronic ulcer ulcers for 20 years, where treatment with available methods failed, amputation of left leg over knee and right leg in tibia



Den 0

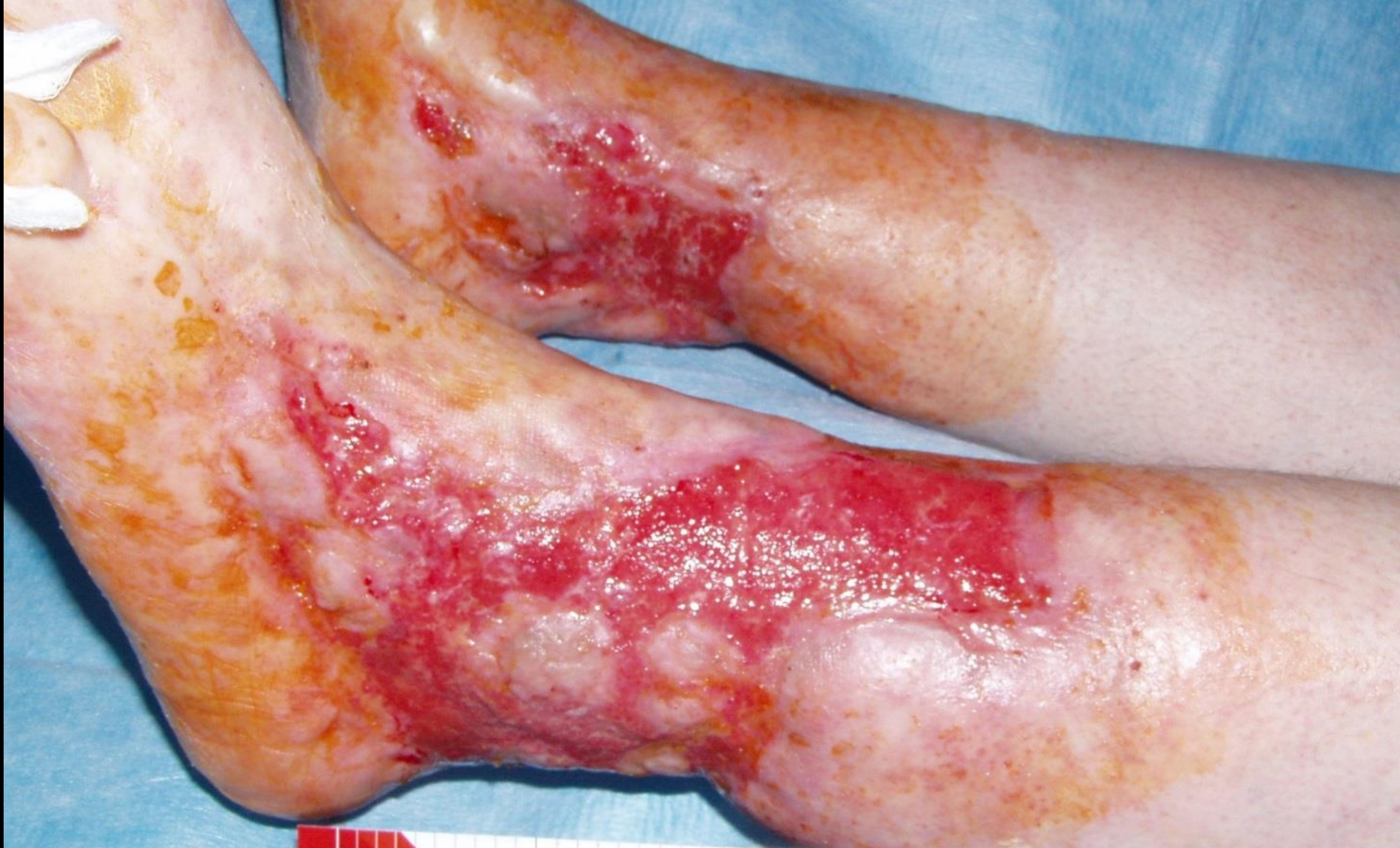

Sorelex
ZJEDNODUŠTE HOJENÍ



Den 41

Sorelex
ZJEDNODUŠTE HOJENÍ



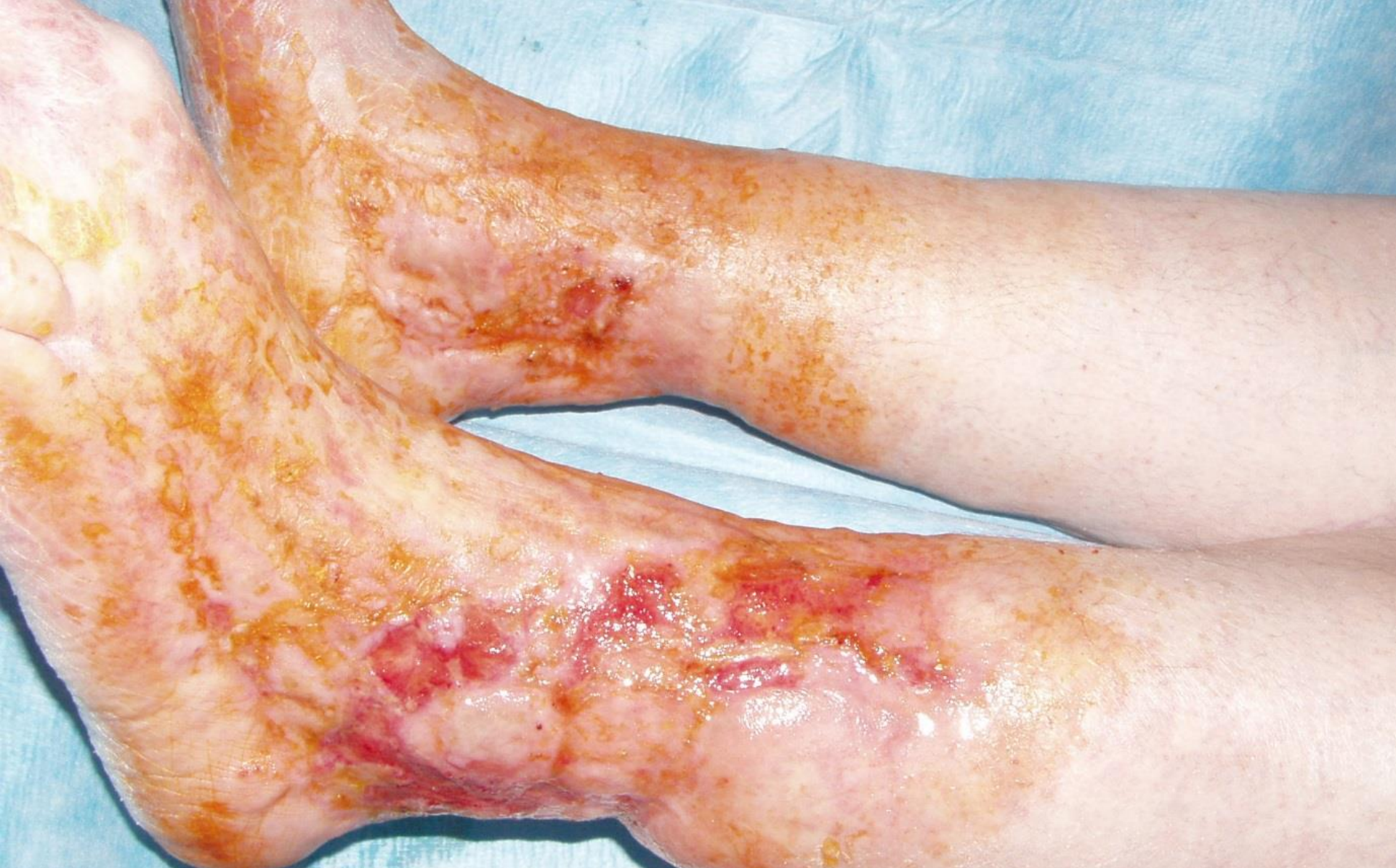Den 71

0 1 2 3 4 5 6 7 8 9 10 11 12 13 14 15 16 17 18 19 20 cm

PATIENT **G. J.**
DATE

CONTIPRO
PHARMA

Sorelex
ZJEDNODUŠTE HOJENÍ



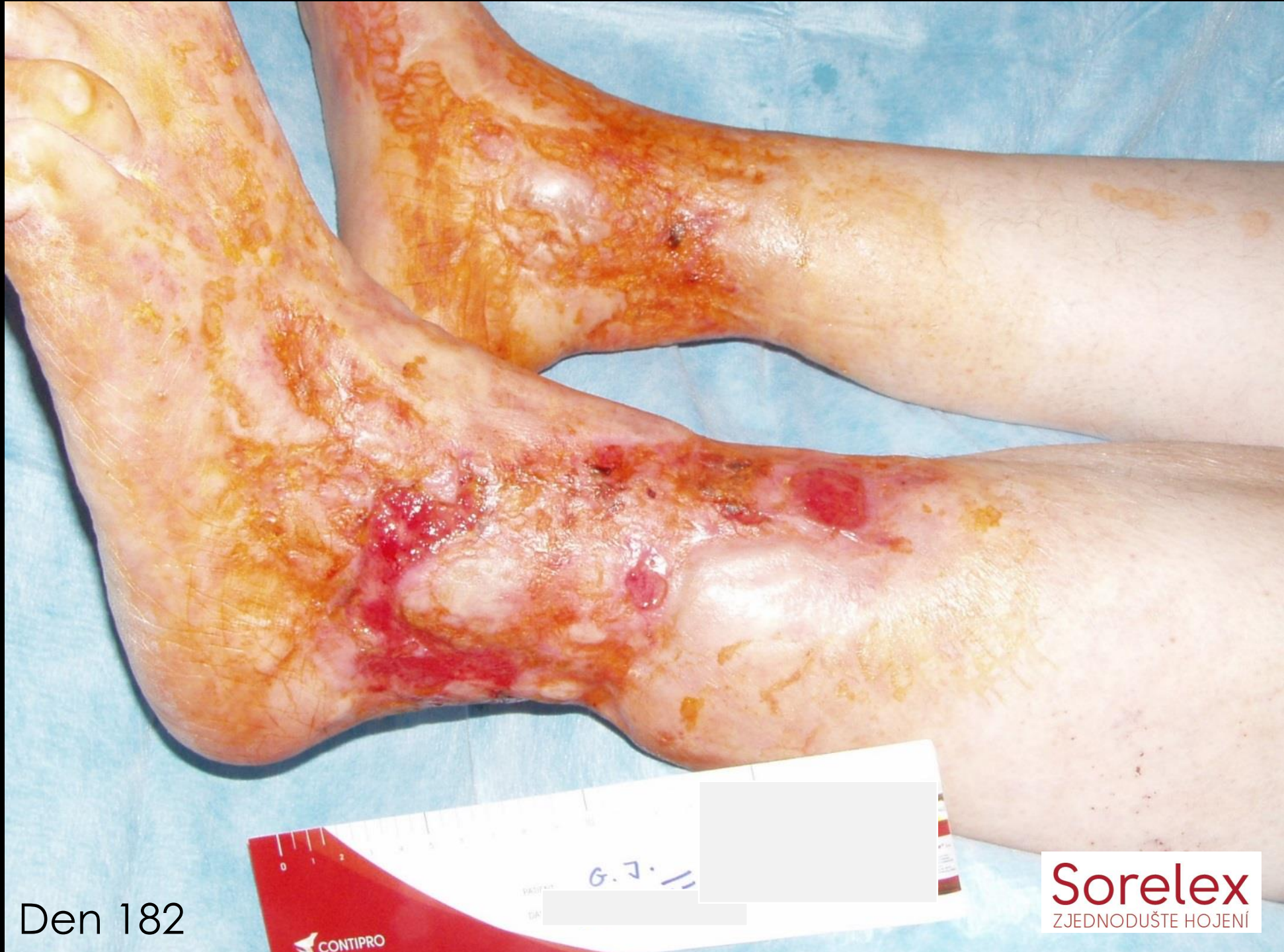Den 134



CONTIPRO
PHARMA

PATIENT 6-1

Sorelex
ZJEDNODUŠTE HOJENÍ

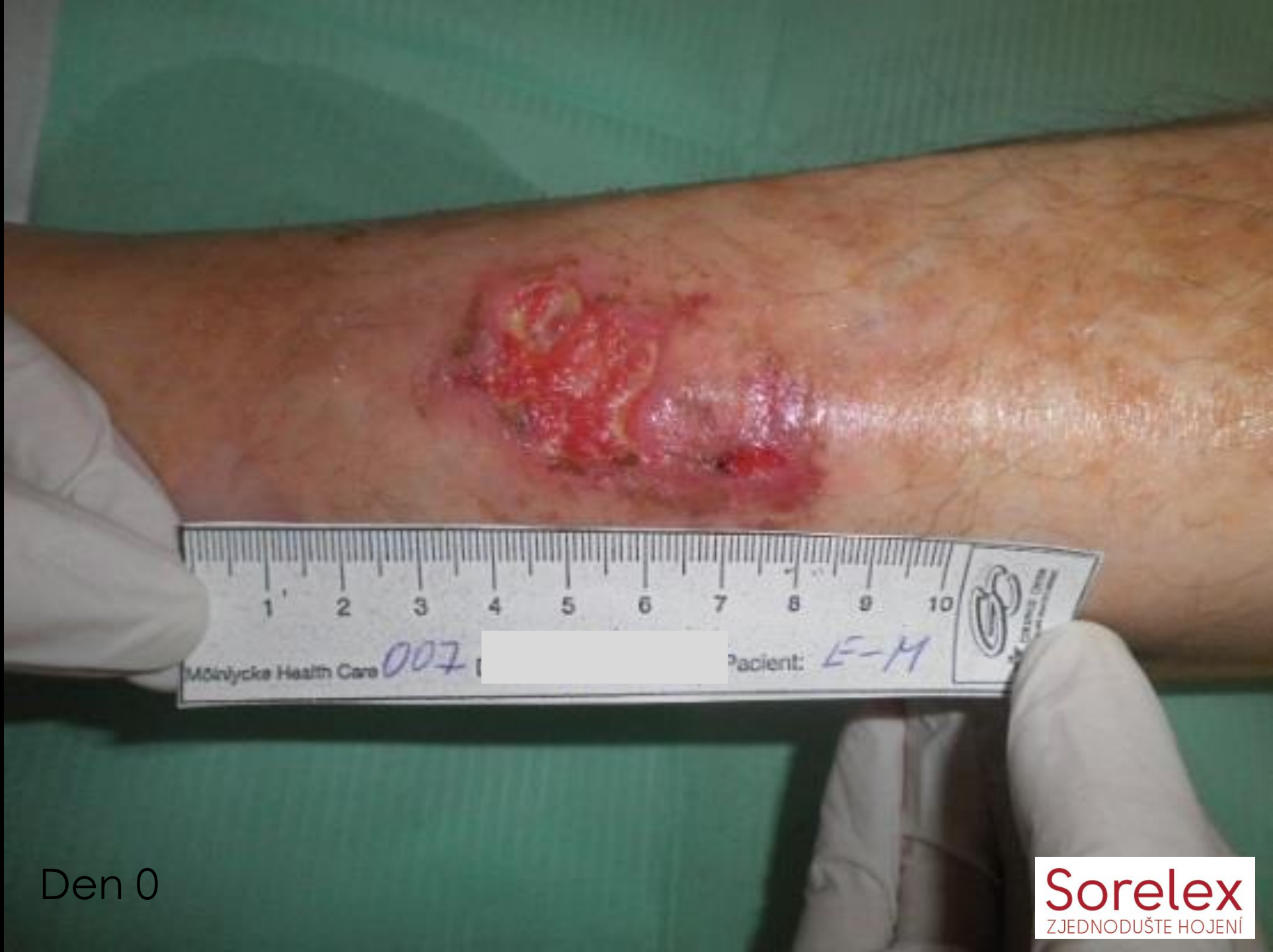

Den 182

Sorelex
ZJEDNODUŠTE HOJENÍ

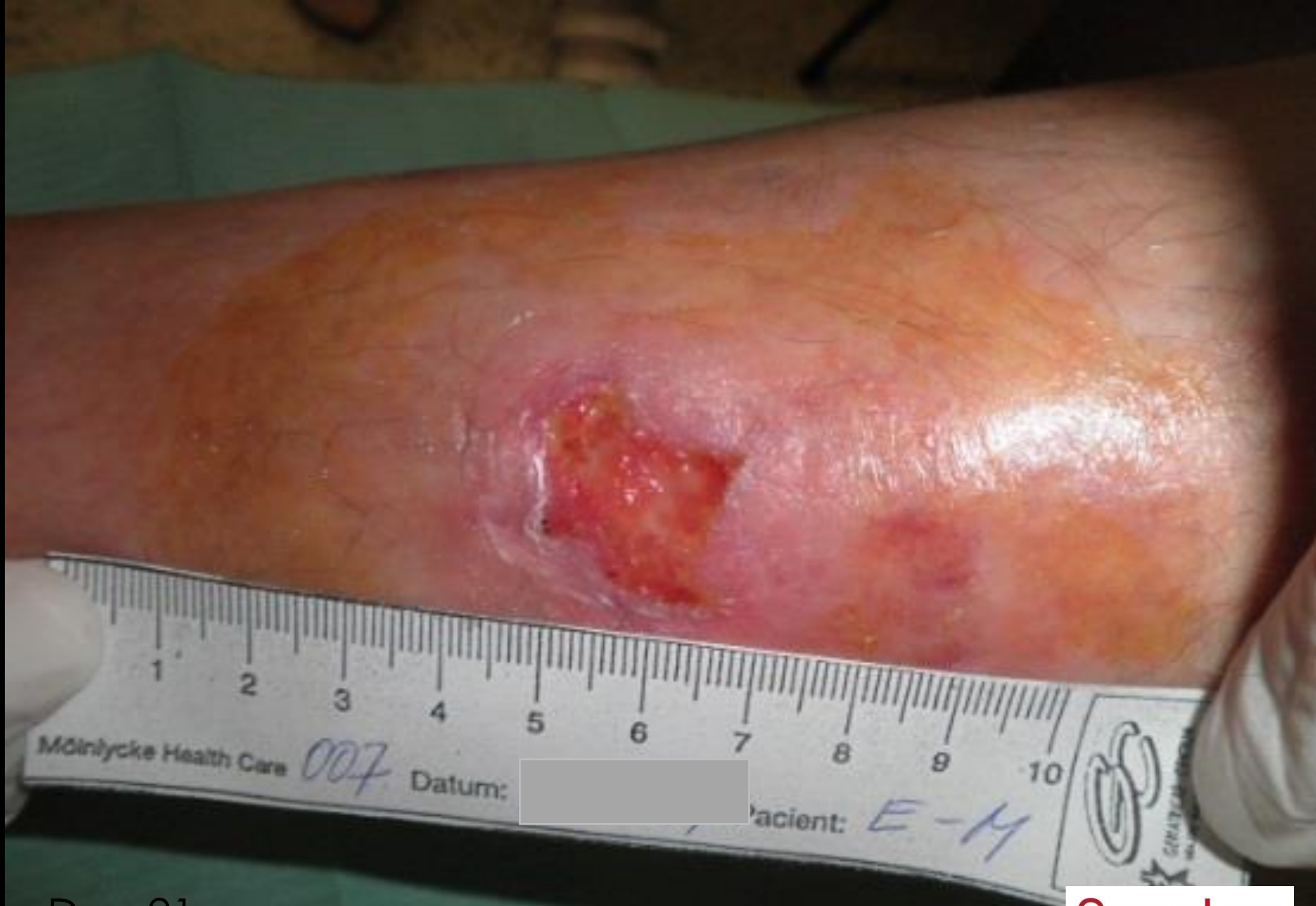Case V - leg ulcer

Patient V: Male, 54 years old, smoker, venous biliary ulcer, Spinoza spinal canal, arterial hypertension, asthma, hypothyreosis, hypercholesterolemia

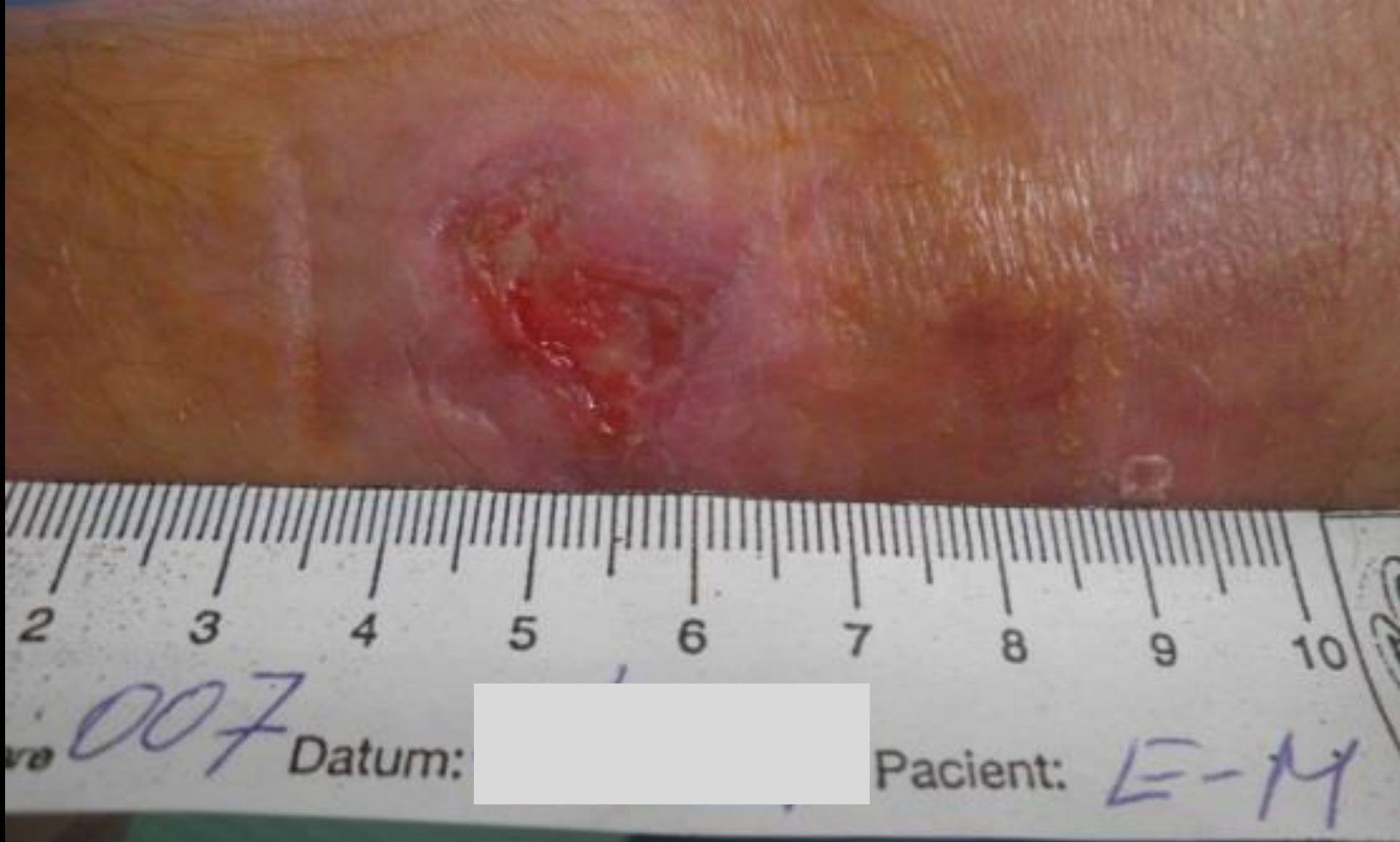

Den 0


Sorelex
ZJEDNODUŠTE HOJENÍ



Den 21

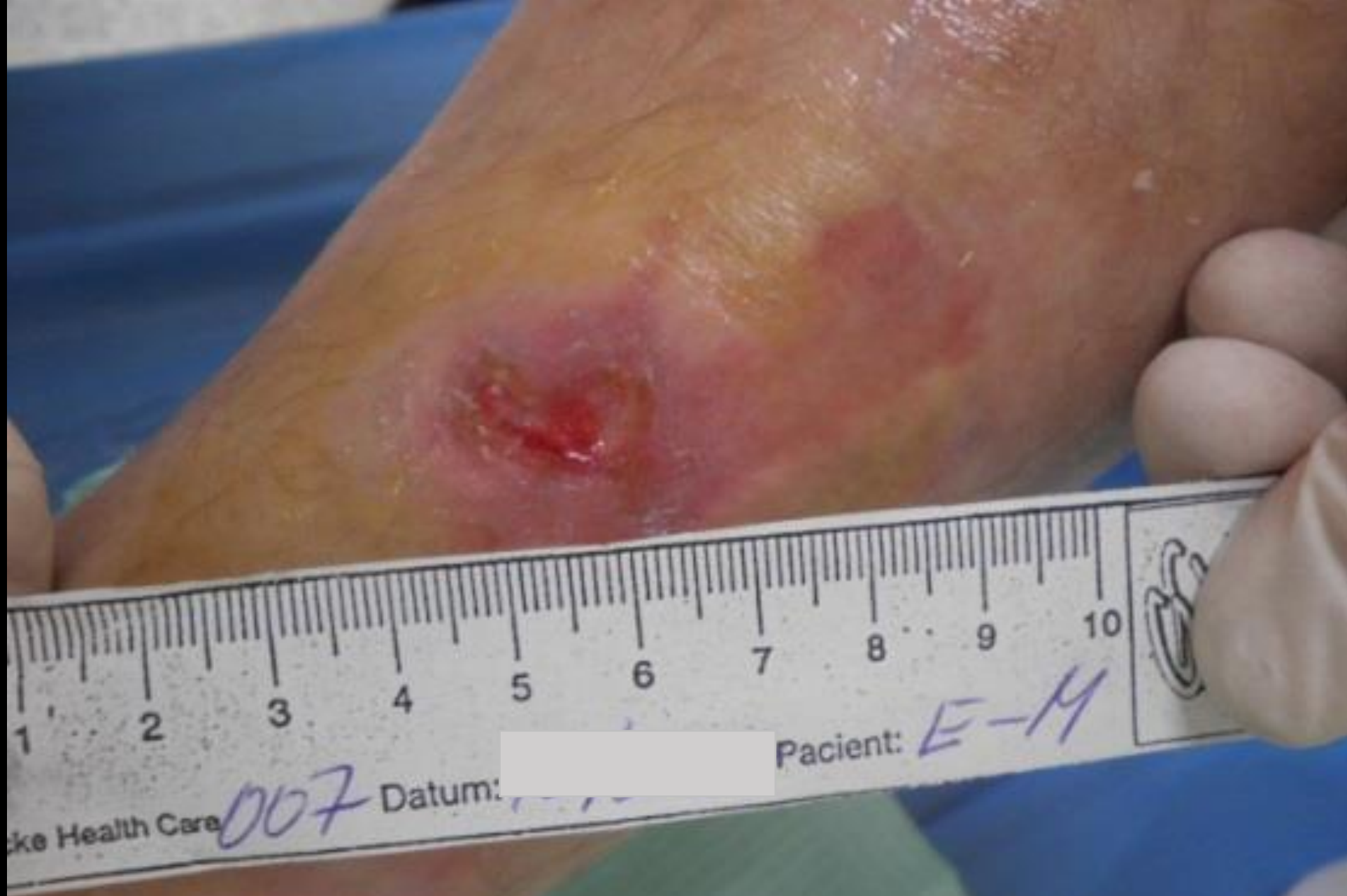

007 Datum:



Pacient: E-M

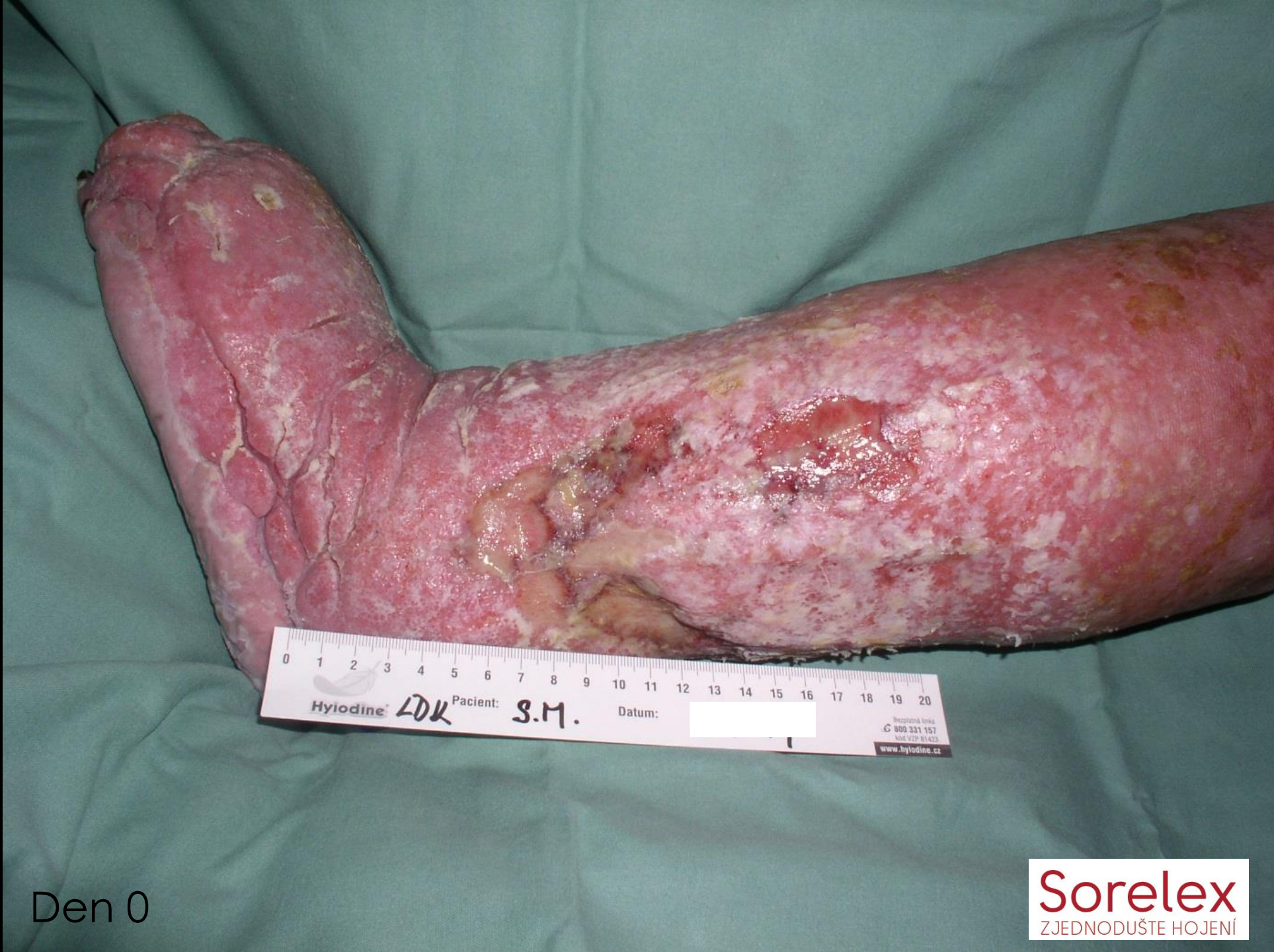Den 28



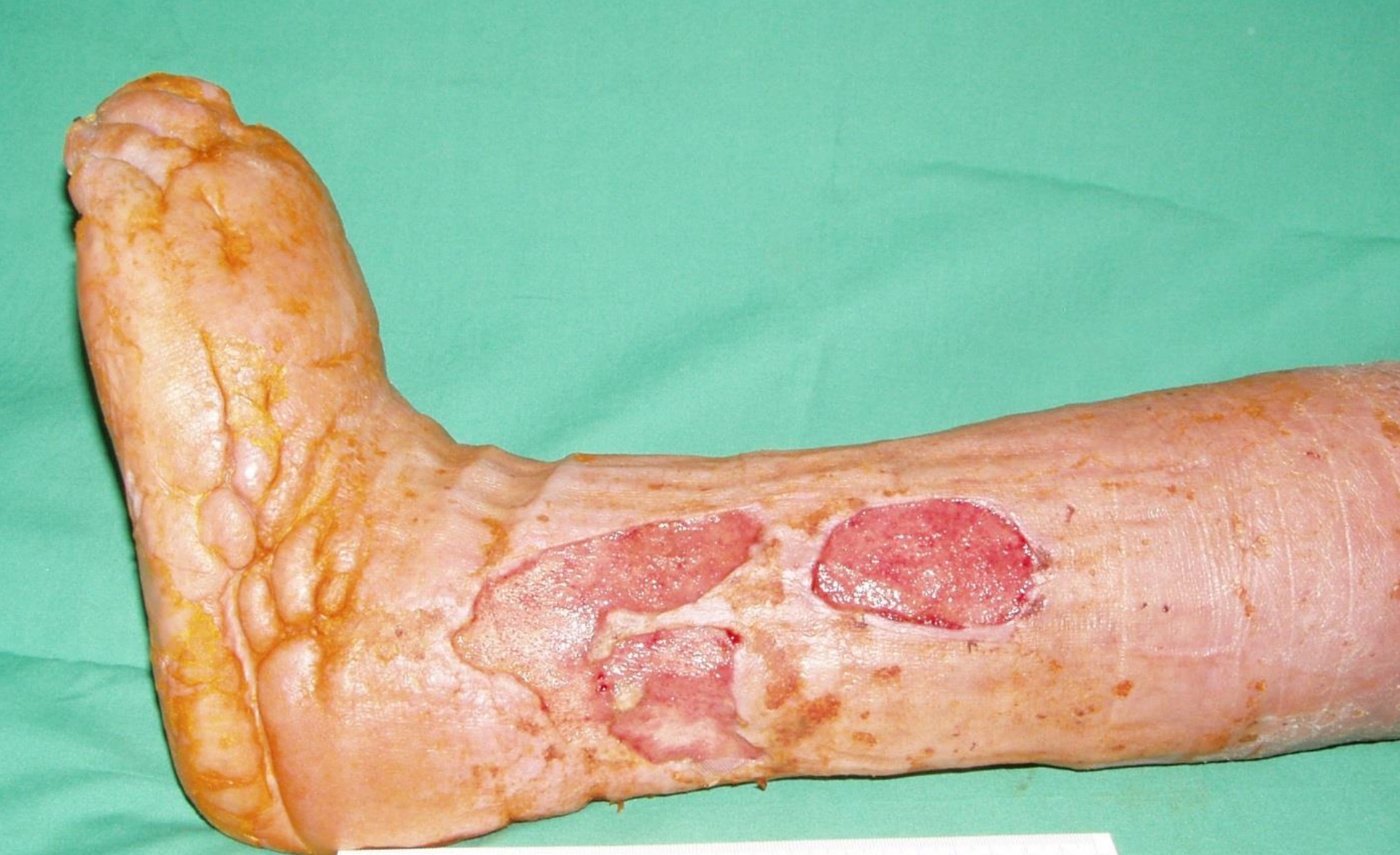Den 35

Case VI - Leg ulcer

Patient VI: Female, S.M., smoker



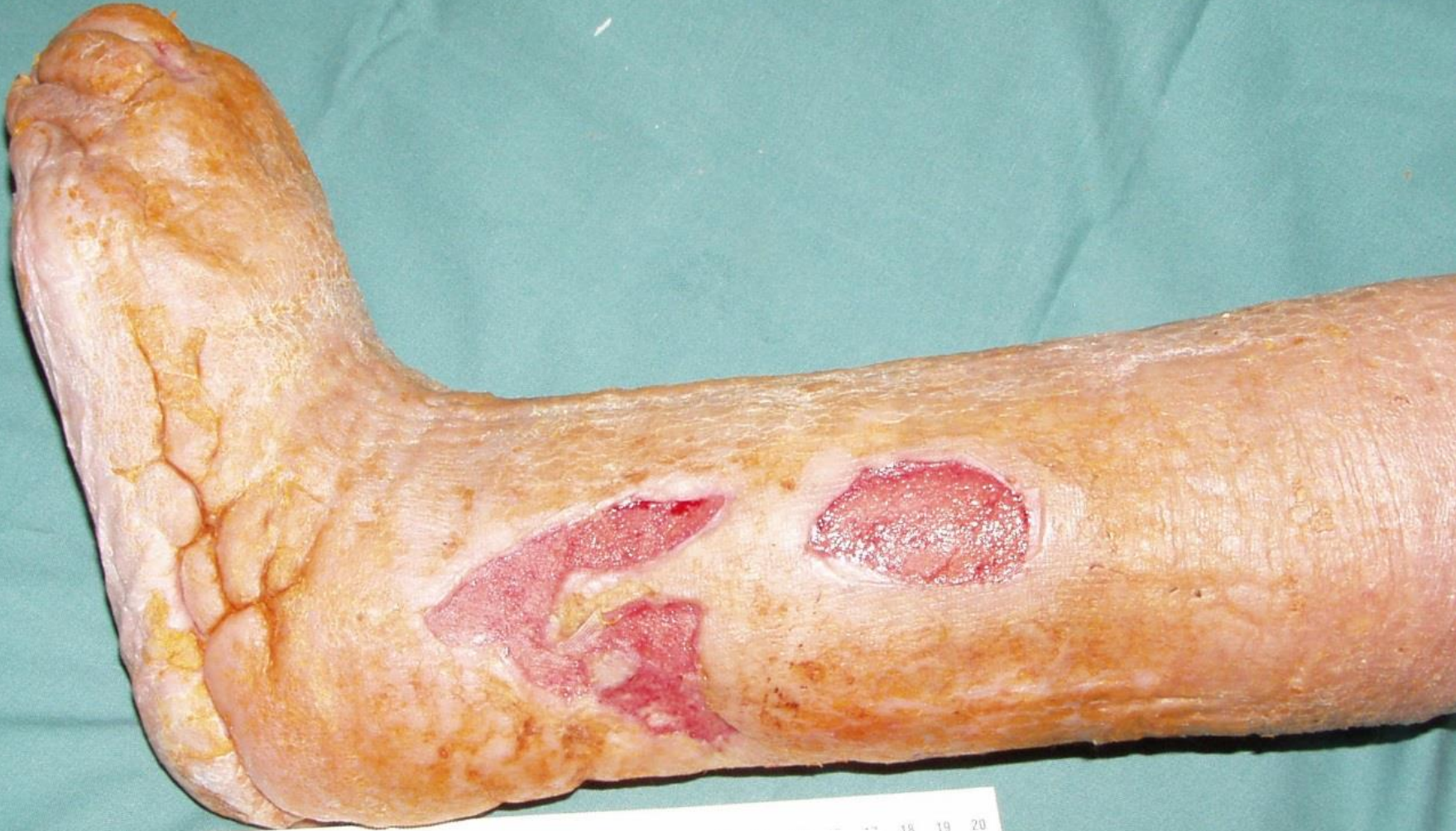Den 0



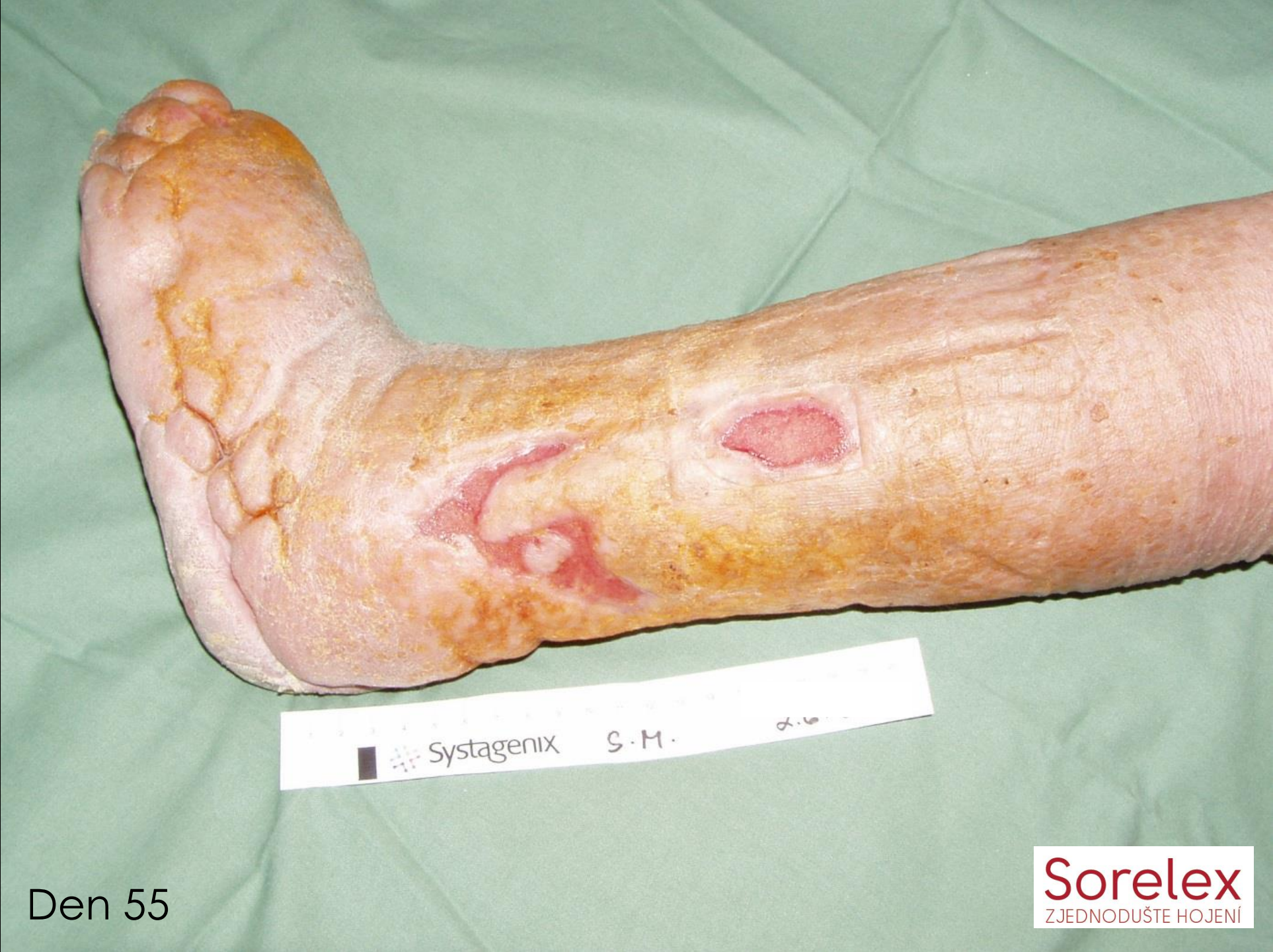0 1 2 3 4 5 6 7 8 9 10 19 20
Pacient: *S.M.* Dat:
Hyiodine
www.hyiodine.cz

Den 14

Sorelex
ZJEDNODUŠTE HOJENÍ



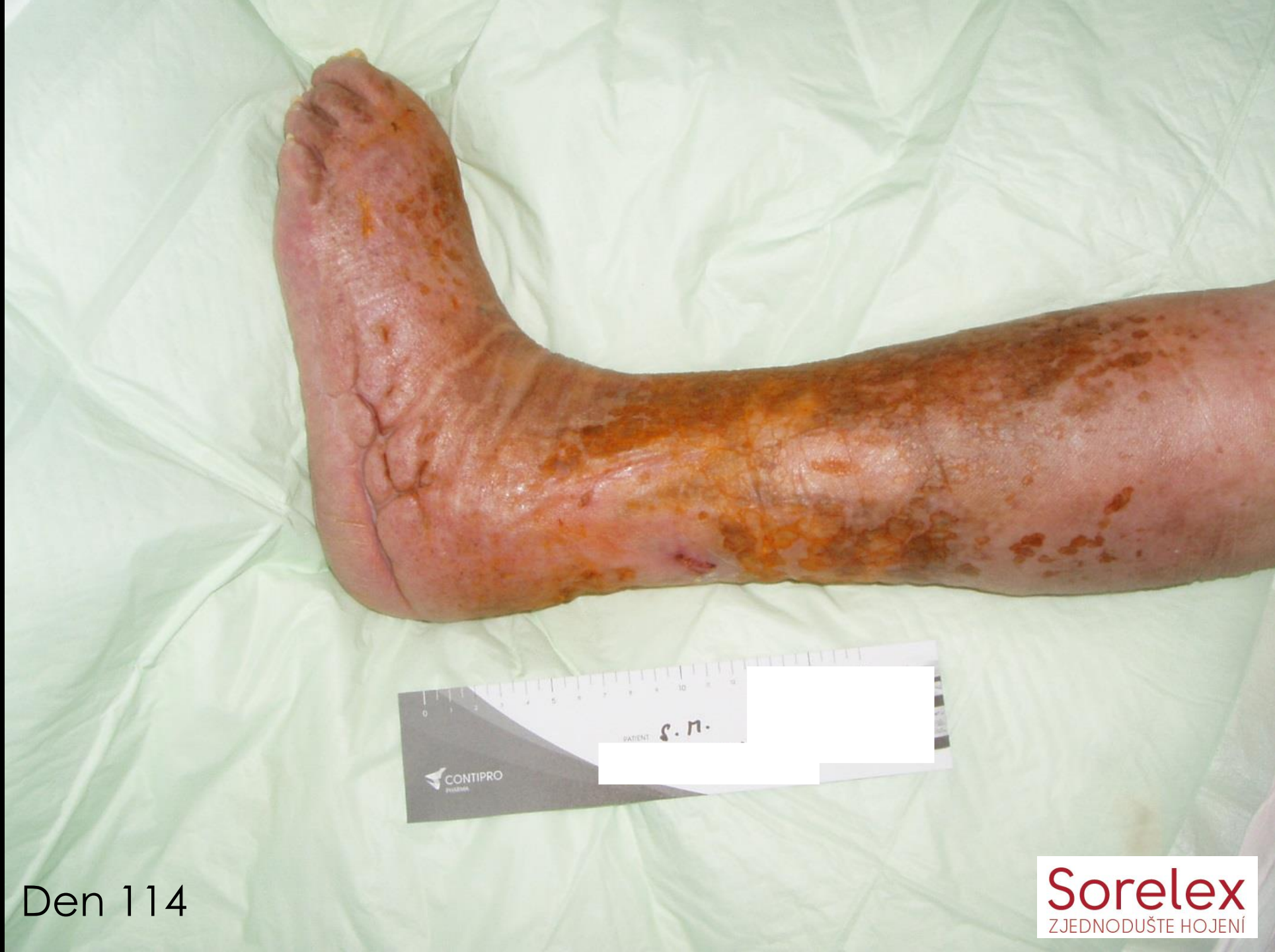Den 34



Systagenix S.M. 2.6

Den 55

Sorelex
ZJEDNODUŠTE HOJENÍ

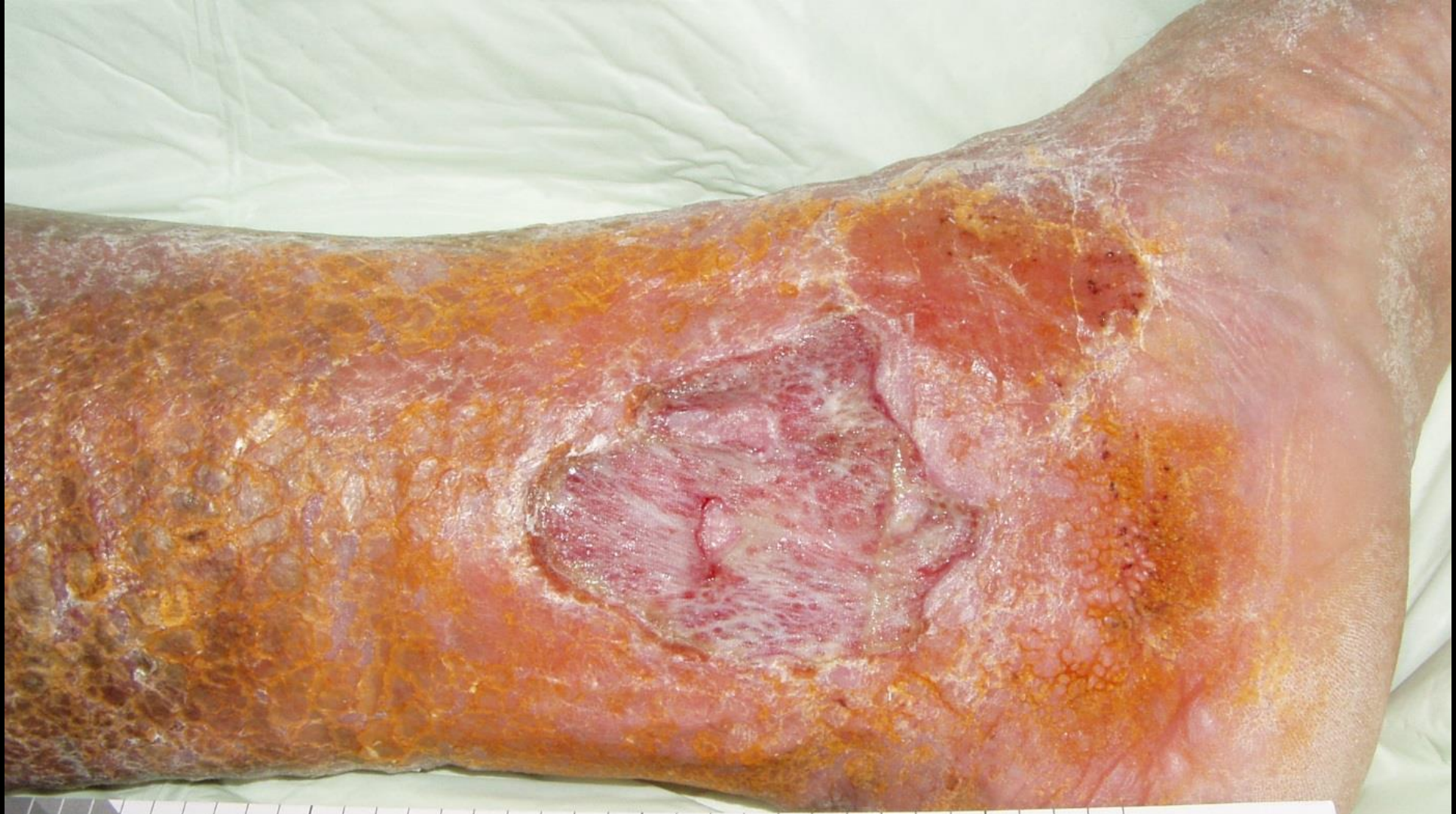

Den 114

Sorelex
ZJEDNODUŠTE HOJENÍ

Case VII - Leg ulcer

Patient VII: Chronic non-healing ulcer, instead of ulcer, is altered by fibrosis. The ulcer failed to heal for 5 years, wound healing until the final healed for a month

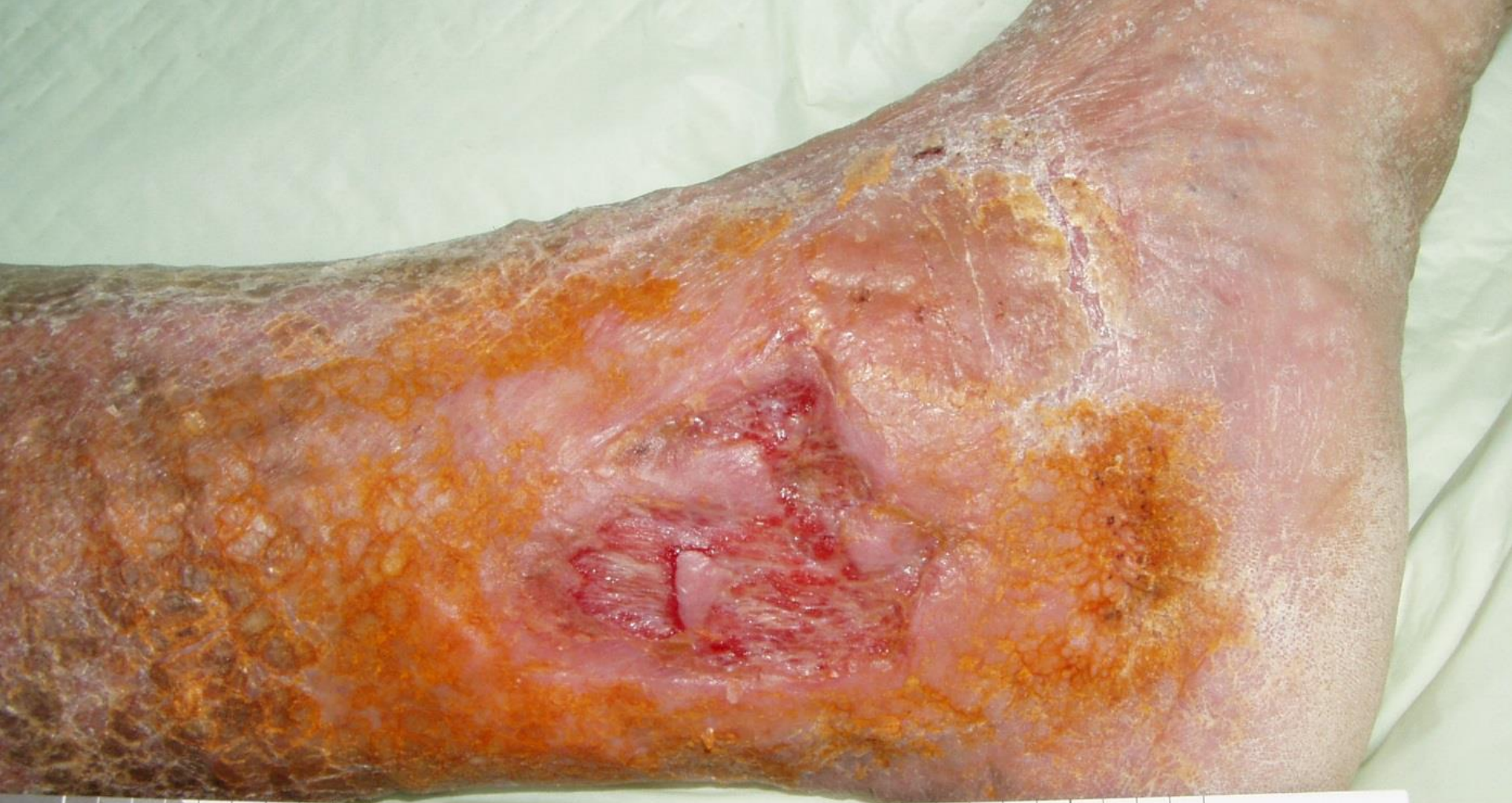

Den 0

PATIENT **C.F.**

D.

Sorelex
ZJEDNODUŠTE HOJENÍ



Den 14

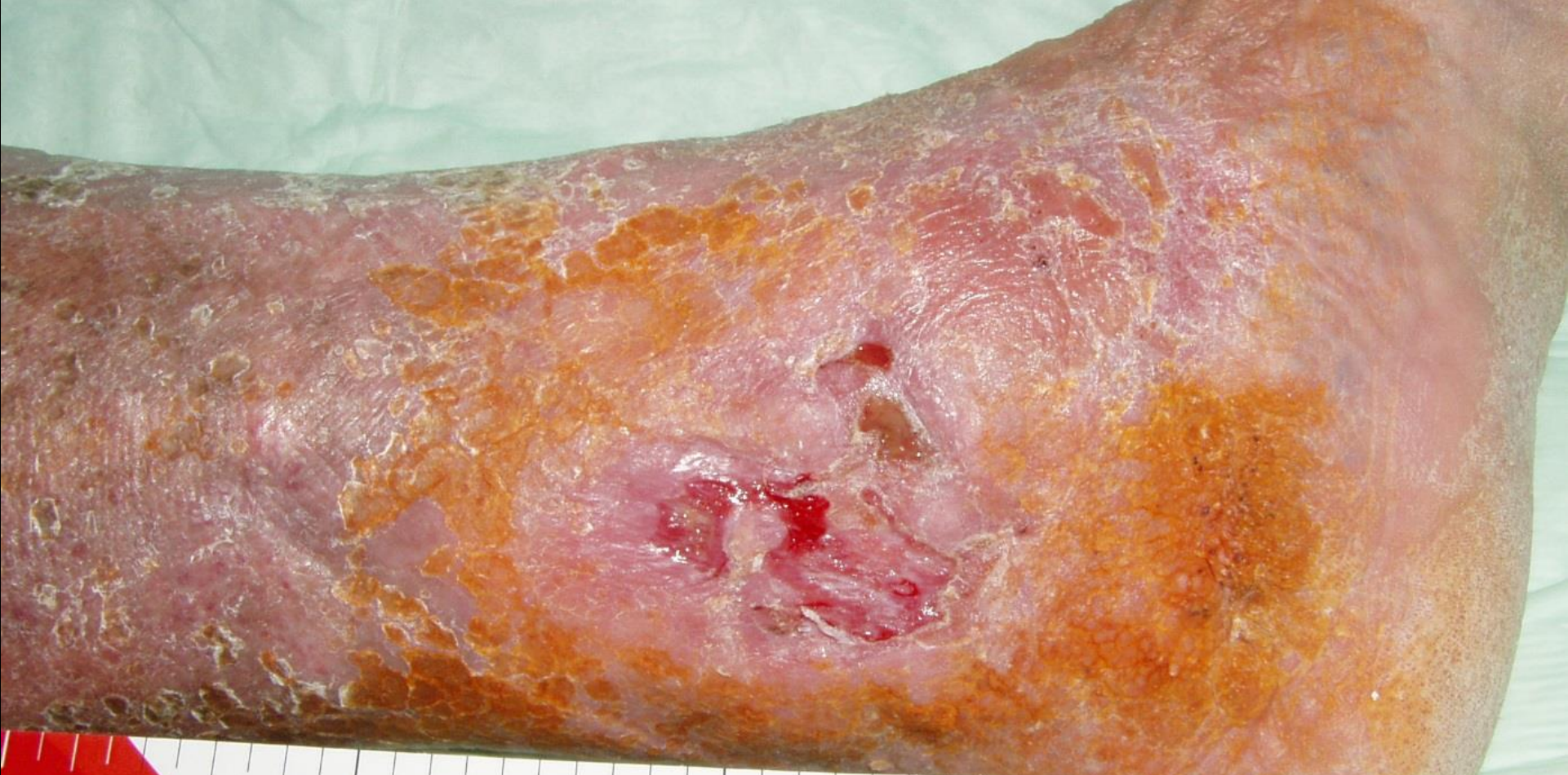PATIENT

C. F.

DA



Sorelex
ZJEDNODUŠTE HOJENÍ



1 2 3 4 5 6 7 8 9 10 11 12 13 14 15 16 17

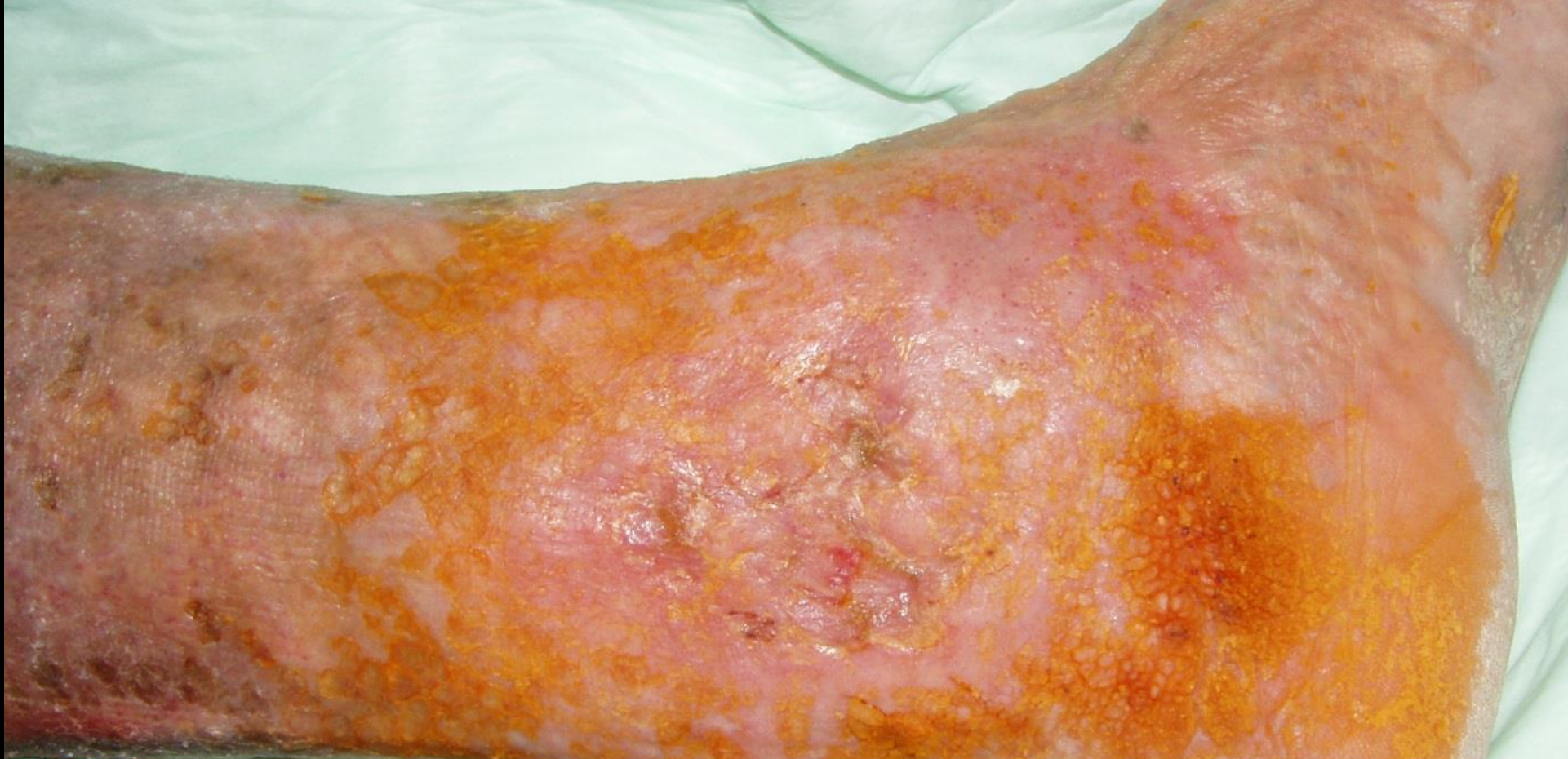PATIENT **Č.F**

DATE

CONTIPRO
PHARMA

Den 28

Sorelex
ZJEDNODUŠTE HOJENÍ



0 1 2 3 4 5 6 7 8 9 10 11 12 13

PATIENT *C.F.*

DATE

CONTIPRO
FARMIA

Den 35

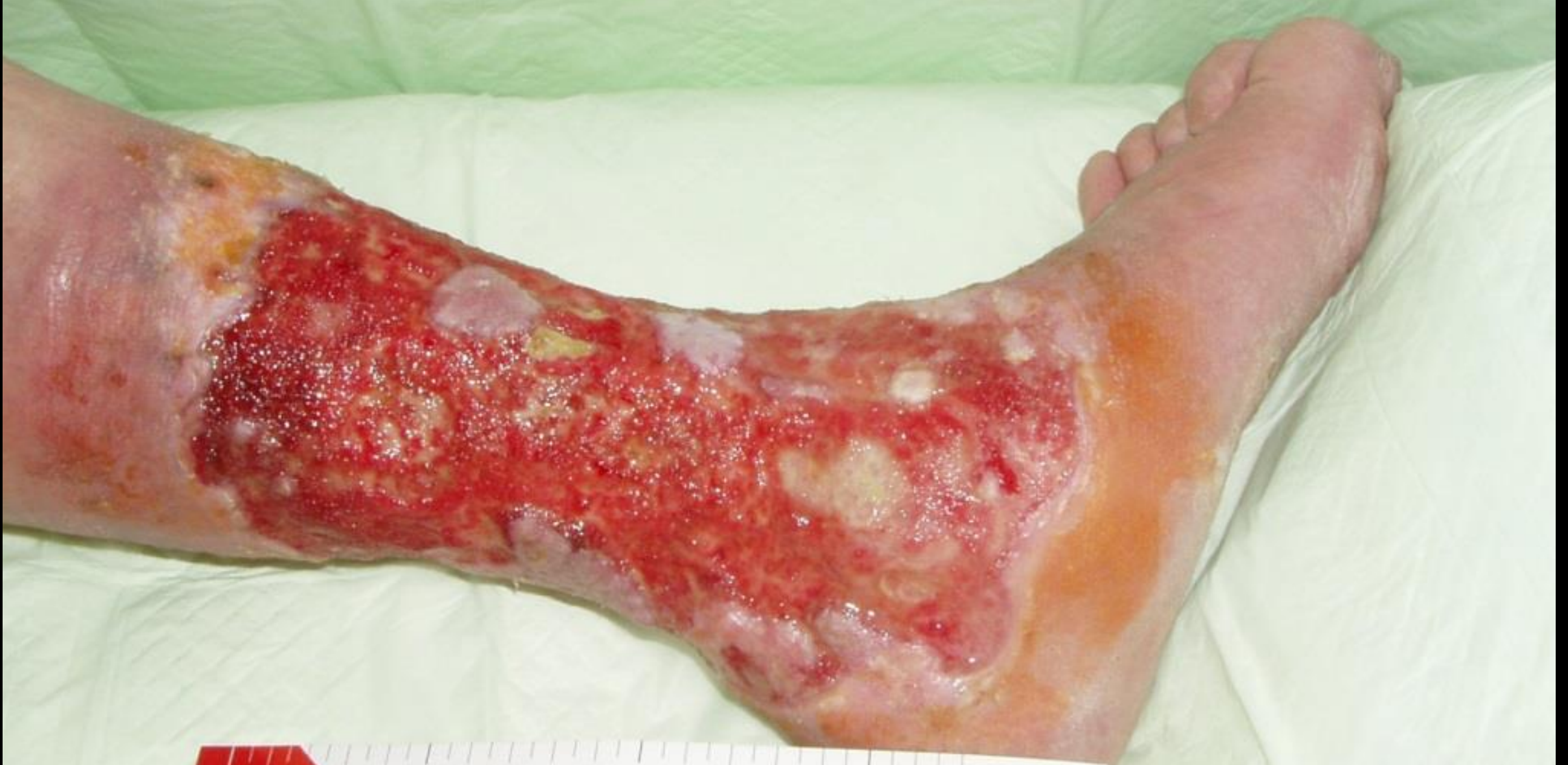Sorelex
ZJEDNODUŠTE HOJENÍ

Case VIII - Comparison with Ag dressing

Patient: female, 82, S.M.

Heavy left ankle arthroplasty, ischemic heart disease, chronic venous insufficiency, DM II type, obesity

The wound is unsuccessfully transplanted and unsuccessful and subsequent wound healing - a lot of materials tested



Den 0

 **CONTIPRO**
PHARMA

PATIENT *S.M.*

DATE

Sorelex
ZJEDNODUŠTE HOJENÍ



Ag dressing

Sorelex

Den 0

Sorelex
ZJEDNODUŠTE HOJENÍ

Ag dressing

Sorelex

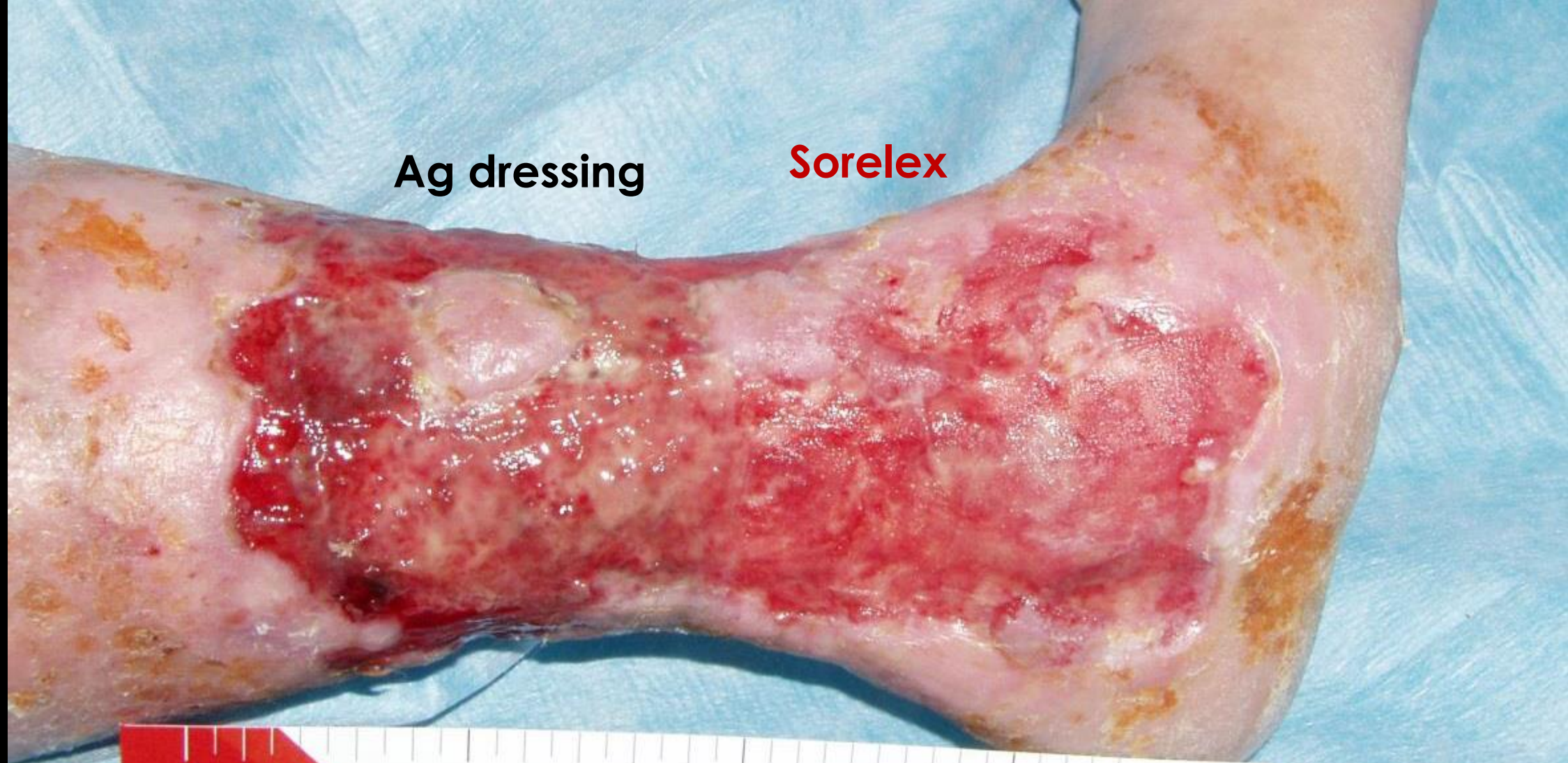
Den 6



Sorelex
ZJEDNODUŠTE HOJENÍ

Ag dressing


Sorelex



0 1 2 3 4 5 6 7 8 9 10 11 12 13 14 15 16 17 cm

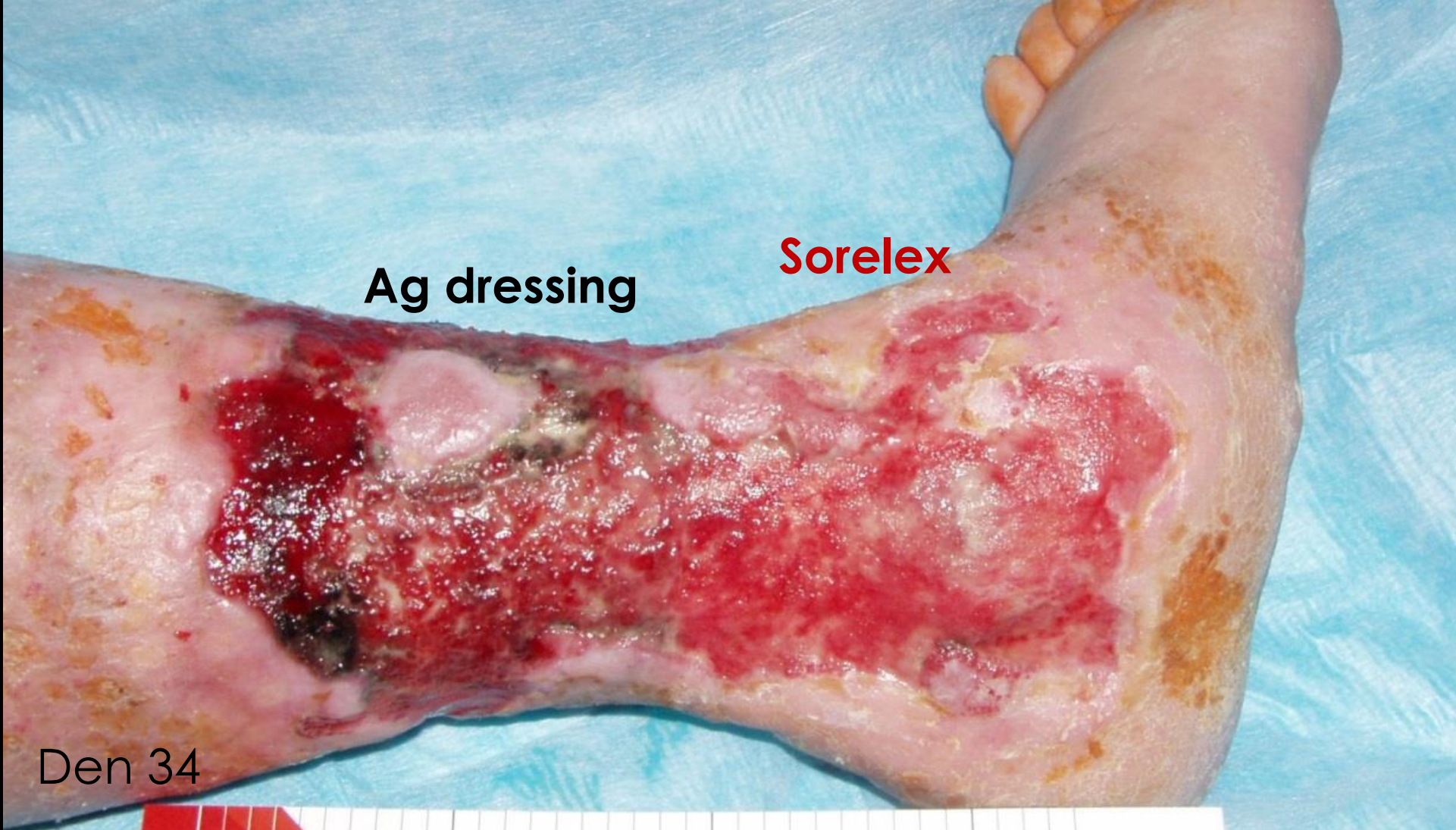
PATIENT **S. M.**

DATE

 **CONTIPRO**
PHARMA

Sorelex
ZJEDNODUŠTE HOJENI

Den 28




Ag dressing

Sorelex

Den 34

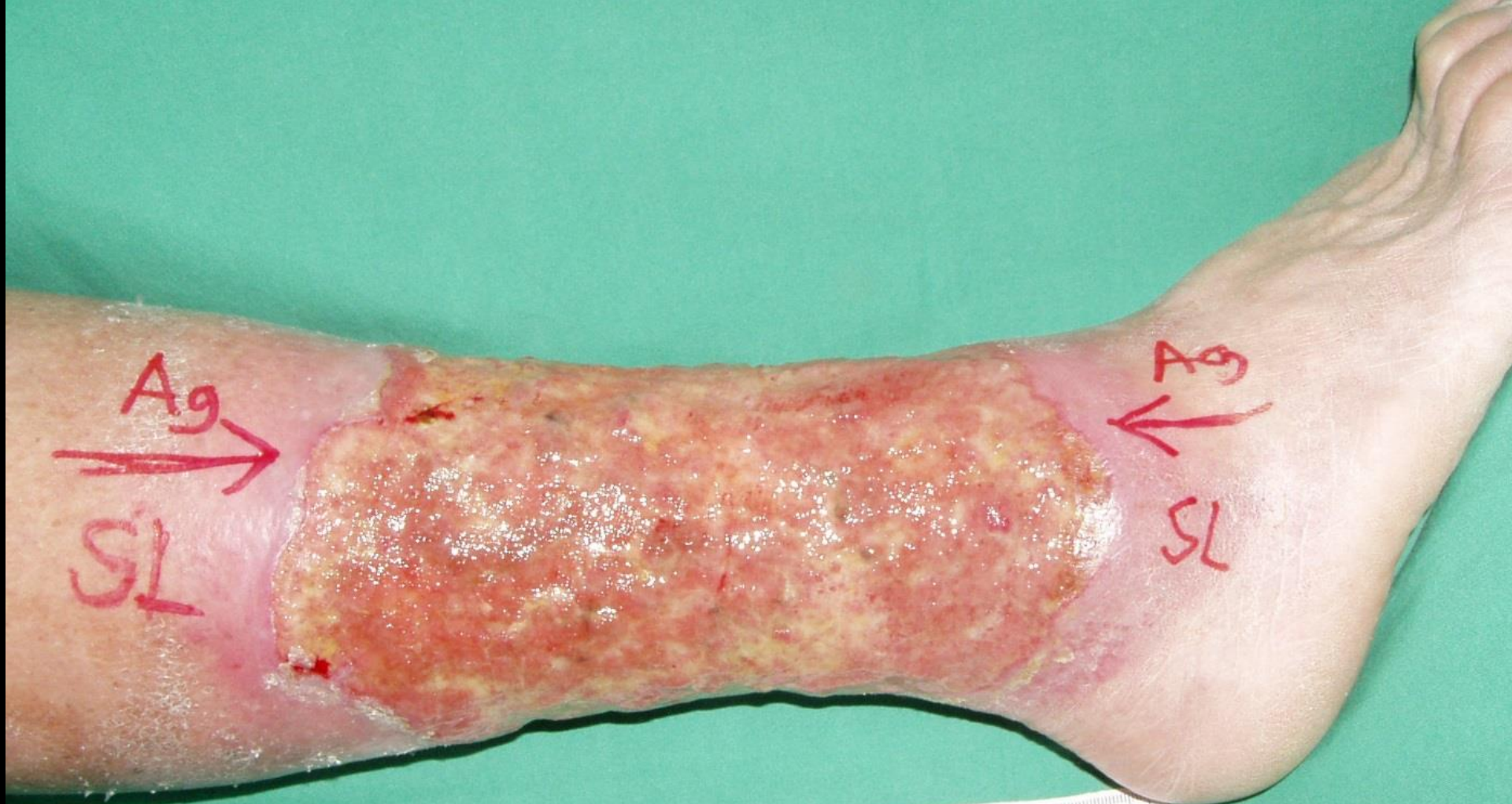
0 1 2 3 4 5 6 7 8 9 10 11 12

PATIENT S.M.
DATE

 **CONTIPRO**
PHARMA

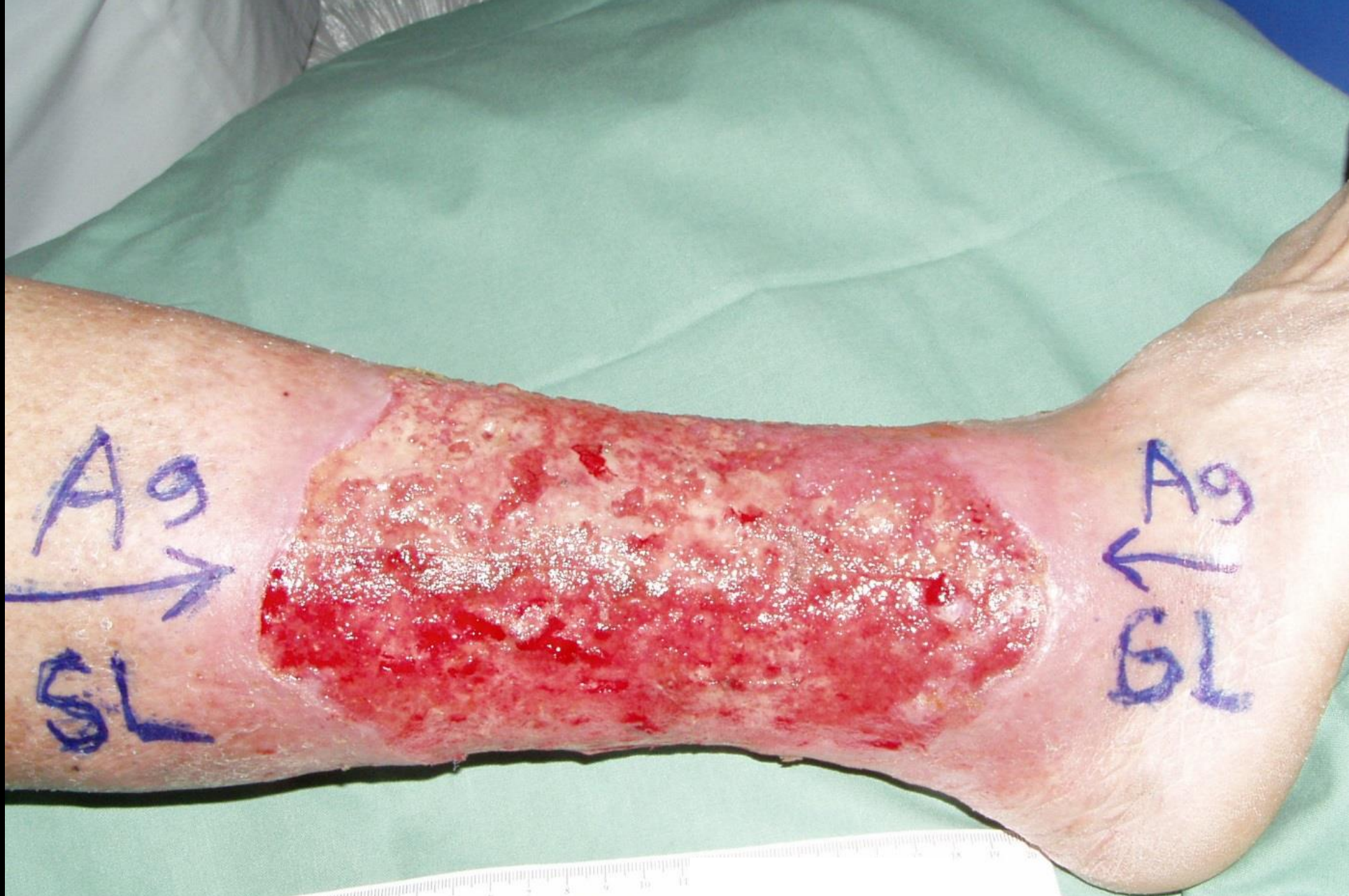Sorelex
ZJEDNODUŠTE HOJENÍ

Case IX - Comparison with Ag dressing




Den 0

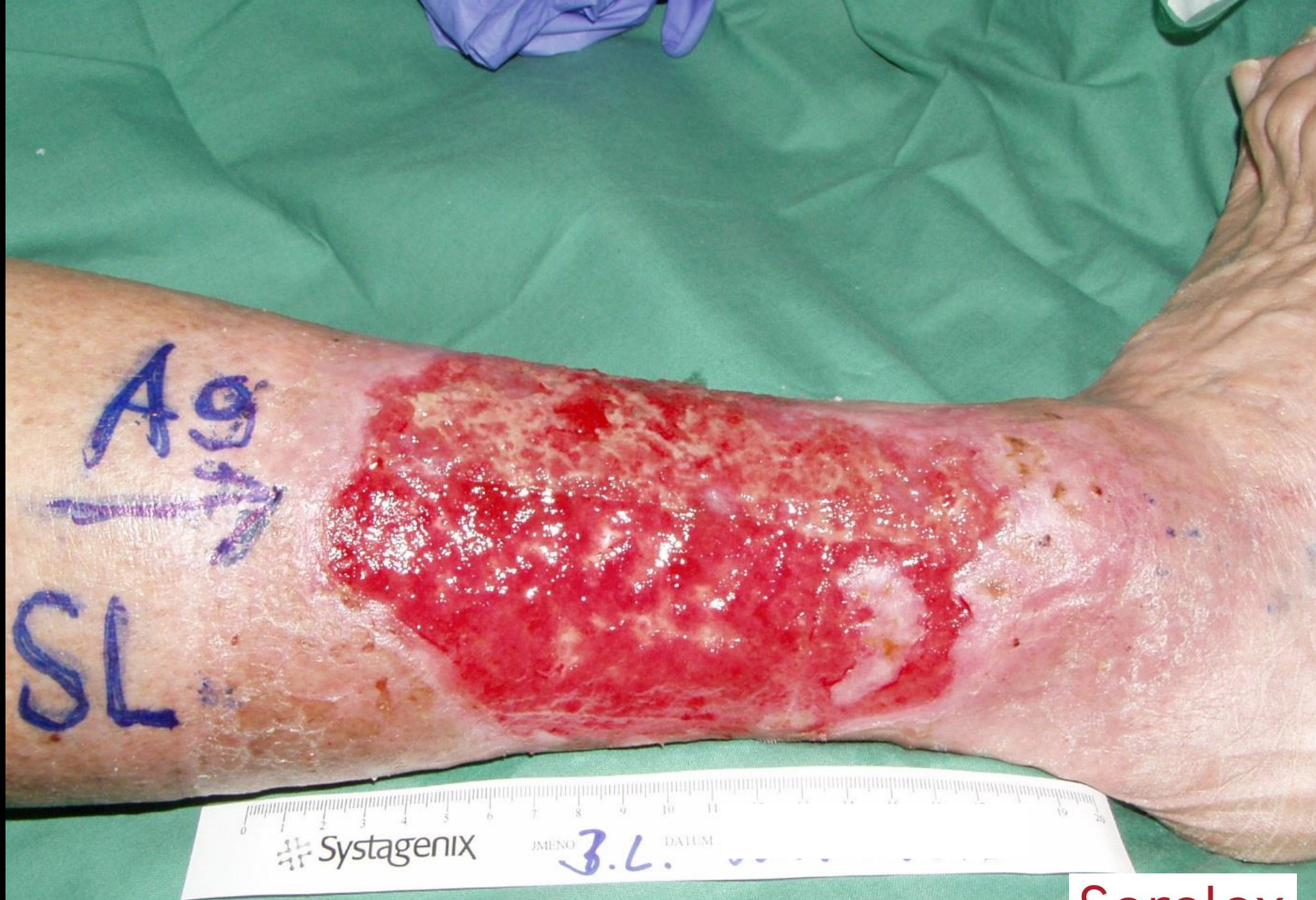Sorelex
ZJEDNODUŠTE HOJENÍ



Den 14



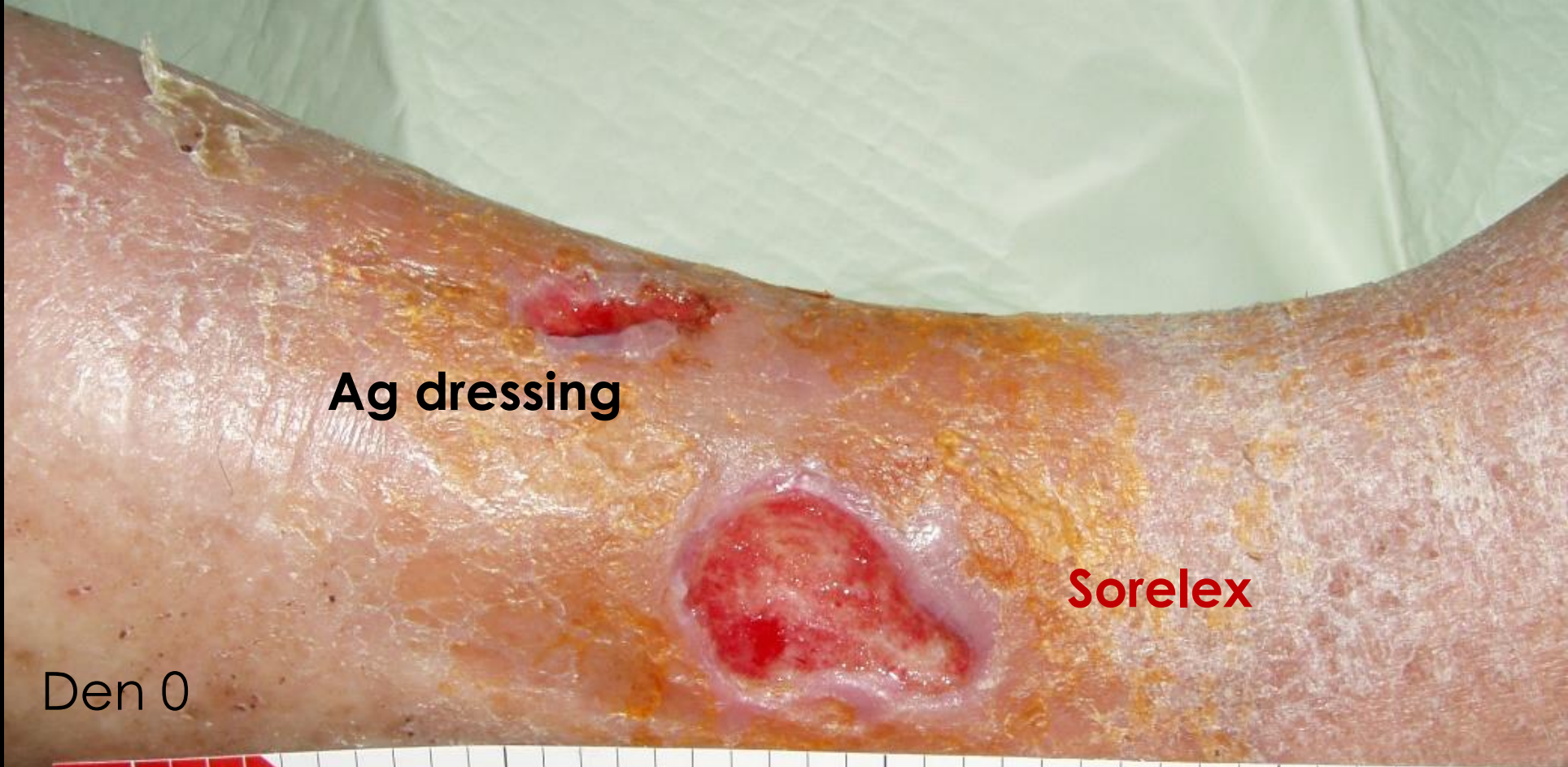Sorelex
ZJEDNODUŠTE HOJENÍ



Den 41

Sorelex
ZJEDNODUŠTE HOJENÍ

Case X - Comparison with Ag dressing



Ag dressing

Sorelex


Den 0



PATIENT

S. J.

DA



Sorelex
ZJEDNODUŠTE HOJENÍ

Ag dressing

Sorelex

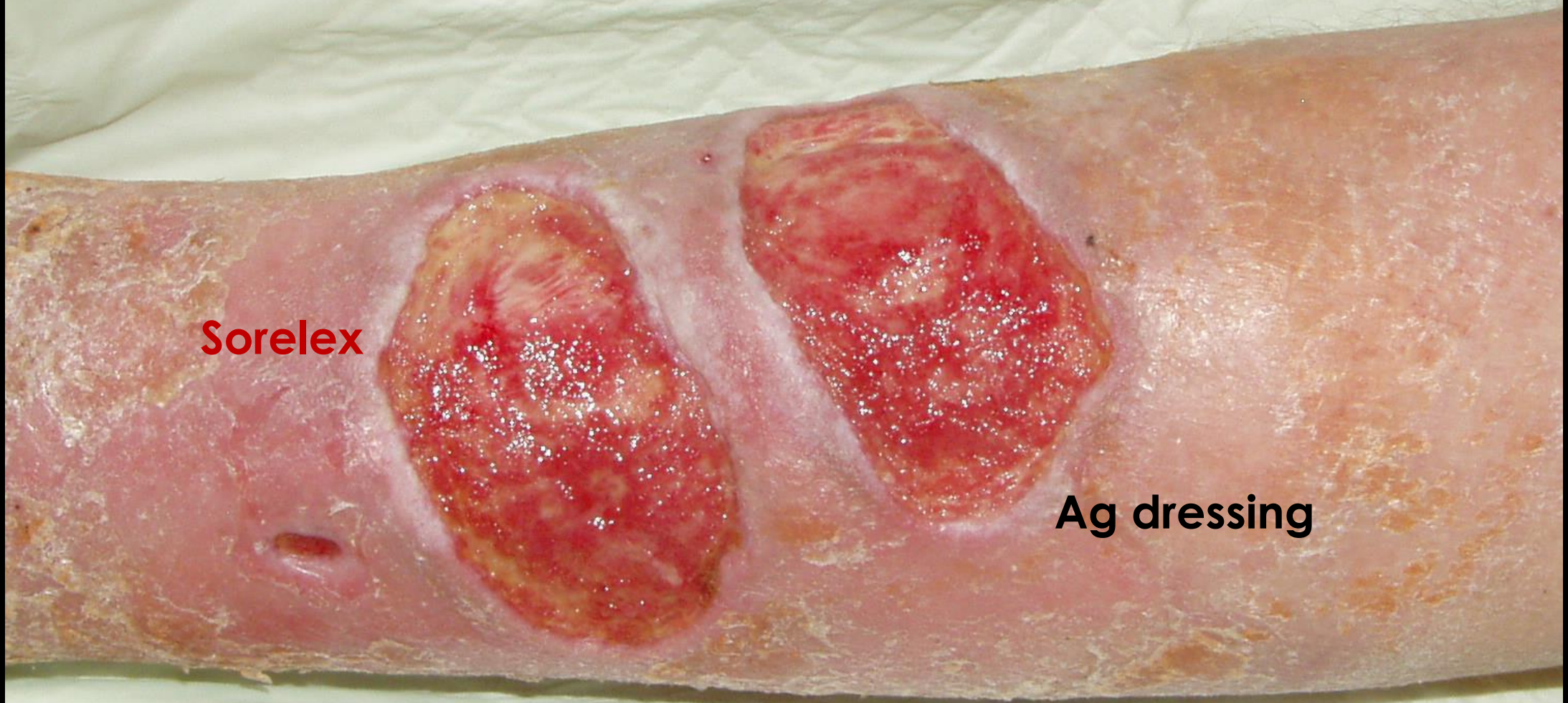Den 42

A red and white ruler is positioned horizontally below the patient's arm. The ruler has a red left end and a white right end, with a scale from 0 to 13 centimeters. Below the scale, a white label reads "PATIENT S.J.". The logo for "CONTIPRO PHARMA" is on the red part of the ruler, and the logo for "Sorelex ZJEDNODUŠTE HOJENÍ" is on the white part.

Case XI - Comparison with Ag dressing

Patient XI: male, 66 years old, obesity, DM II type, chronic venous insufficiency, coronary heart disease, peripheral arterial disease

Two non-healing wounds for 53 weeks, all previous treatments unsuccessful



Sorelex

Ag dressing

Den 0



PATIENT **B.S.**
DATE

Sorelex
ZJEDNODUŠTE HOJENÍ

Sorelex

Ag dressing

Den 35

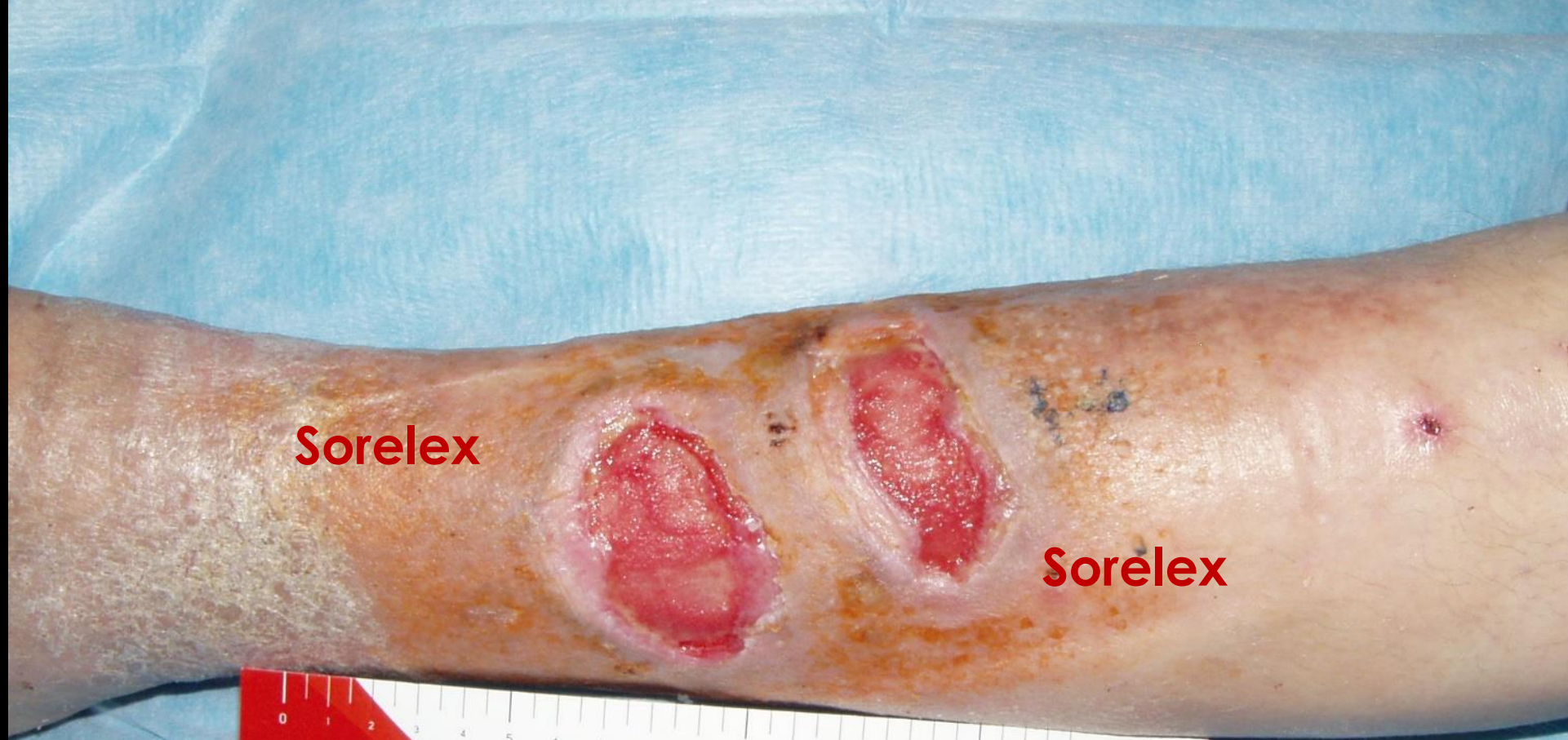 **CONTIPRO**
PHARMA

PATIENT

B. M.

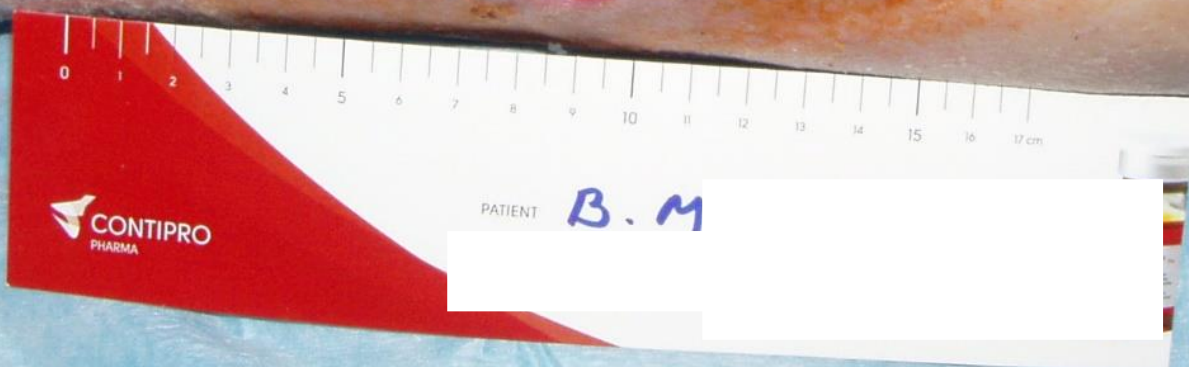DATE

Sorelex
ZJEDNODUŠTE HOJENÍ



Sorelex

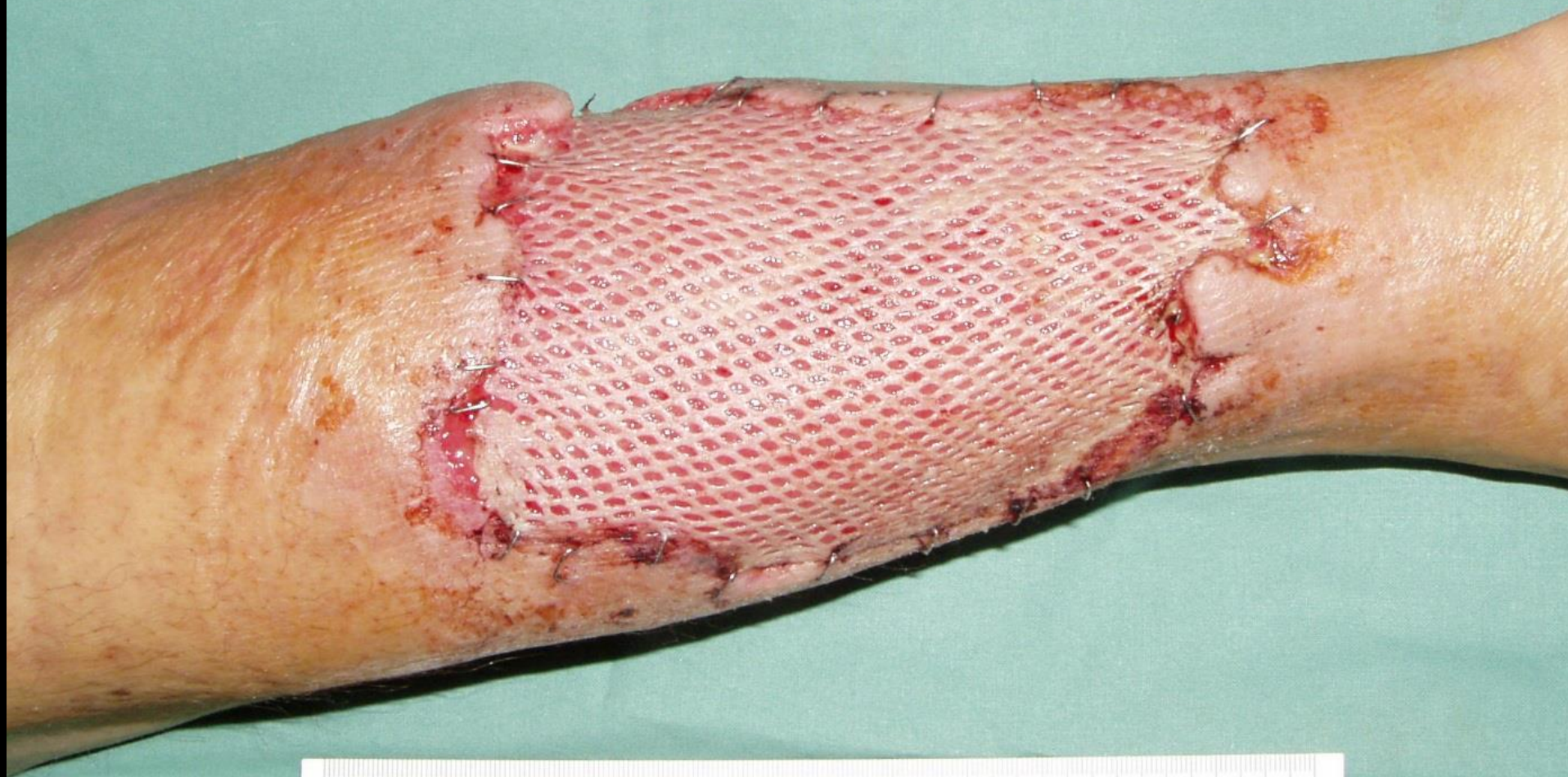
Sorelex



Den 47

Sorelex
ZJEDNODUŠTE HOJENÍ

Case Study XII - Skin transplantation



0 1 2 3 4 5 6 7 8 9 10 11 12 13 14 15 16 17 18 19 20

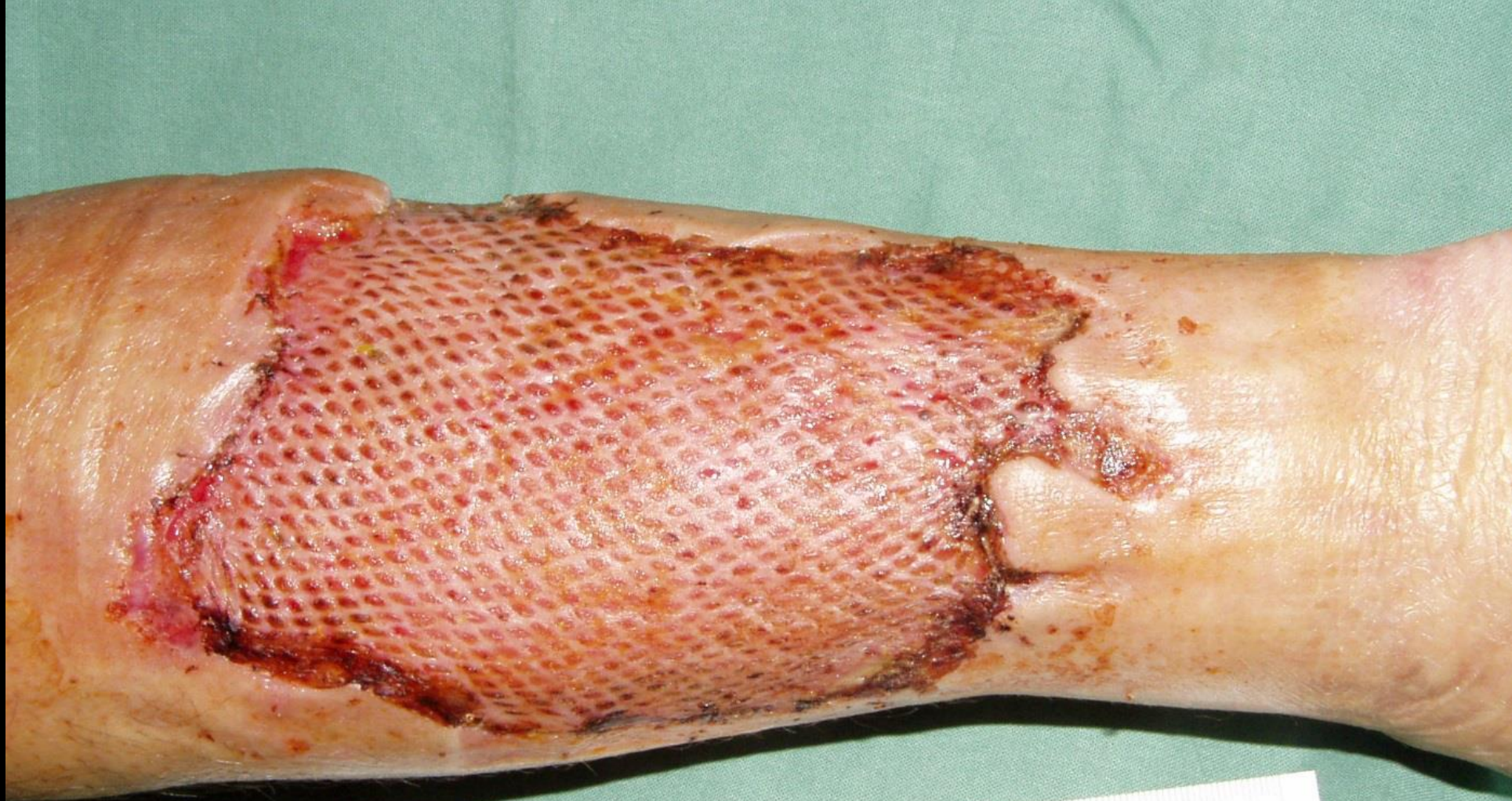Hyiodine[®]

Pacient: **M.J.**

Bezpl.
800 :
kód V:
www.hyio

Den 0

Sorelex
ZJEDNODUŠTE HOJENÍ



0 1 2 3 4 5 6 7 8 9 10 11 12 13 14 15 16 17 18 19 20

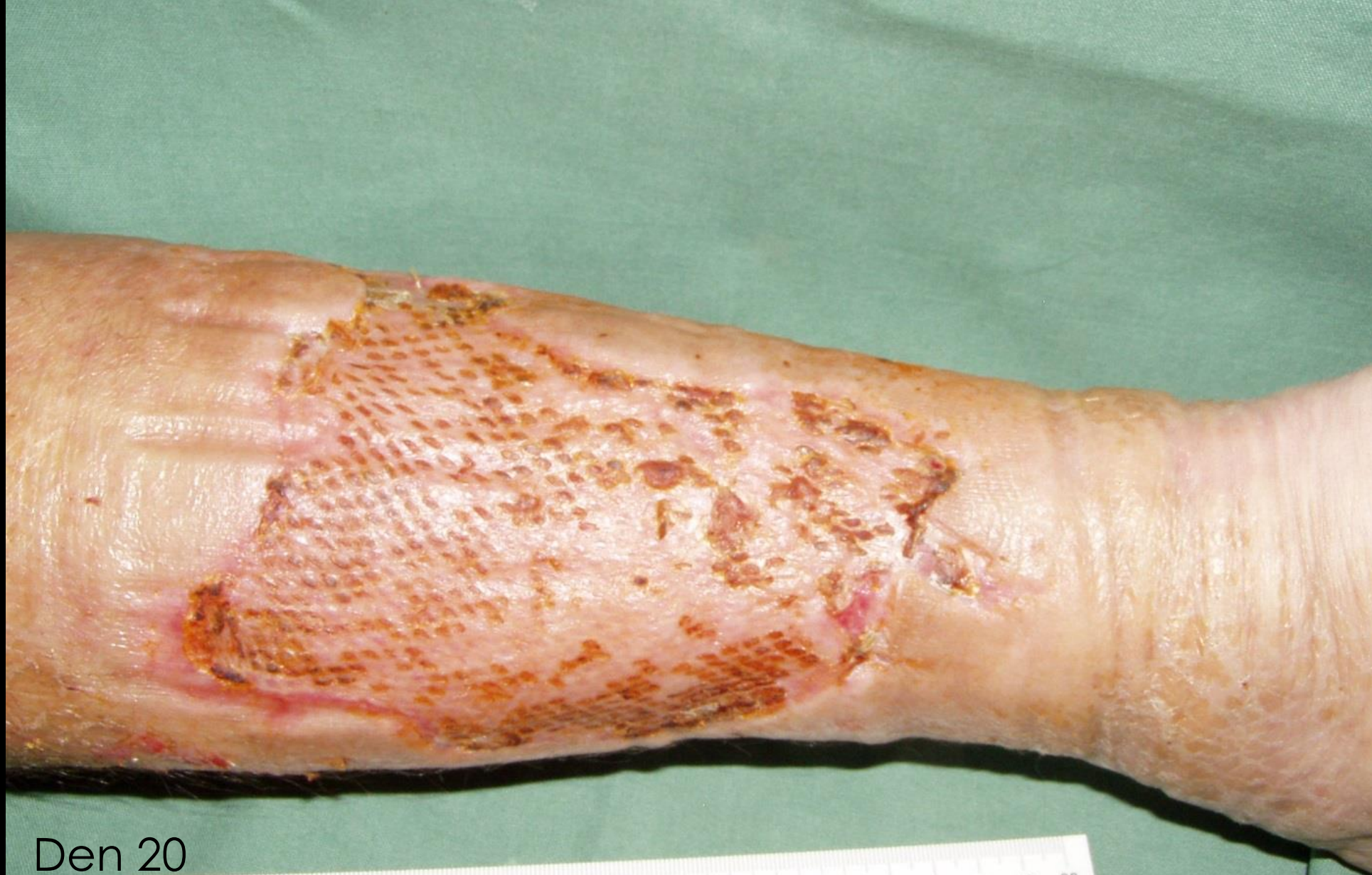Bezplatná linka
800 331 157
MUDr. VZP 81423
www.hyiodine.cz

Hyiodine®

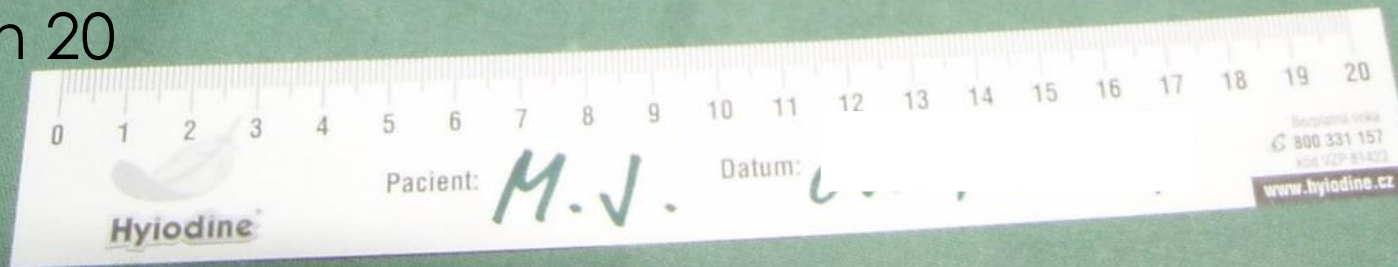
Pacient: **M. J.** Datum: **...**

Den 6

Sorelex
ZJEDNODUŠTE HOJENÍ



Den 20



Sorelex
ZJEDNODUŠTE HOJENÍ



Sorelex

ZJEDNODUŠTE HOJENÍ

